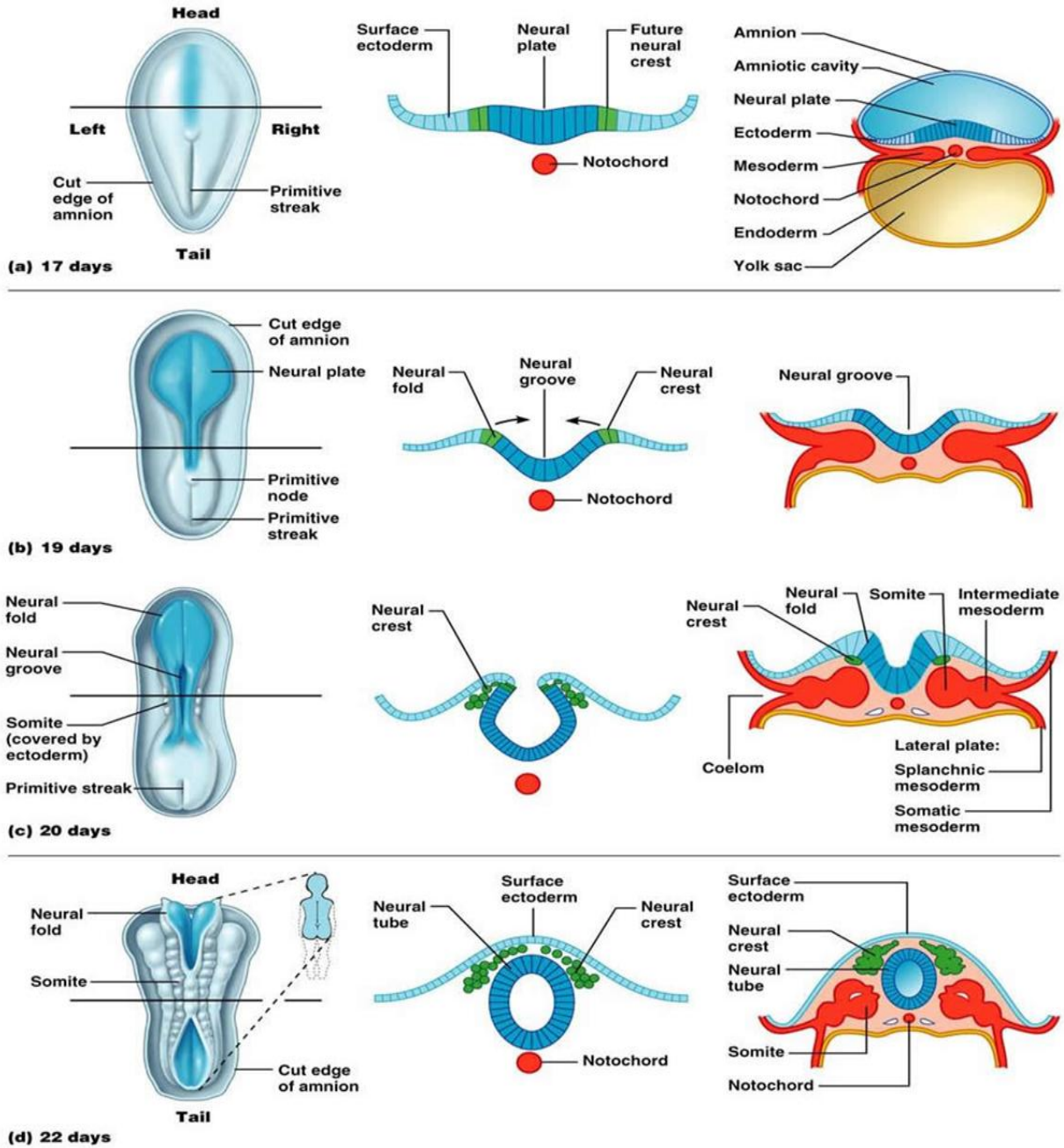
Head
Left
Right
Cut edge of amnion
Primitive streak
Tail
(a) 17 days
Surface ectoderm
Neural plate
Future neural crest
Notochord
Amnion
Amniotic cavity
Neural plate
Ectoderm
Mesoderm
Notochord
Endoderm
Yolk sac
Cut edge of amnion
Neural plate
Primitive node
Primitive streak
(b) 19 days
Neural fold
Neural groove
Neural crest
Notochord
Neural groove
Neural fold
Neural groove
Somite (covered by ectoderm)
Primitive streak
(c) 20 days
Neural crest
Neural crest
Neural fold
Somite
Intermediate mesoderm
Coelom
Lateral plate:
Splanchnic mesoderm
Somatic mesoderm
Head
Neural fold
Somite
Cut edge of amnion
Tail
(d) 22 days
Surface ectoderm
Neural tube
Neural crest
Notochord
Surface ectoderm
Neural crest
Neural tube
Somite
Notochord

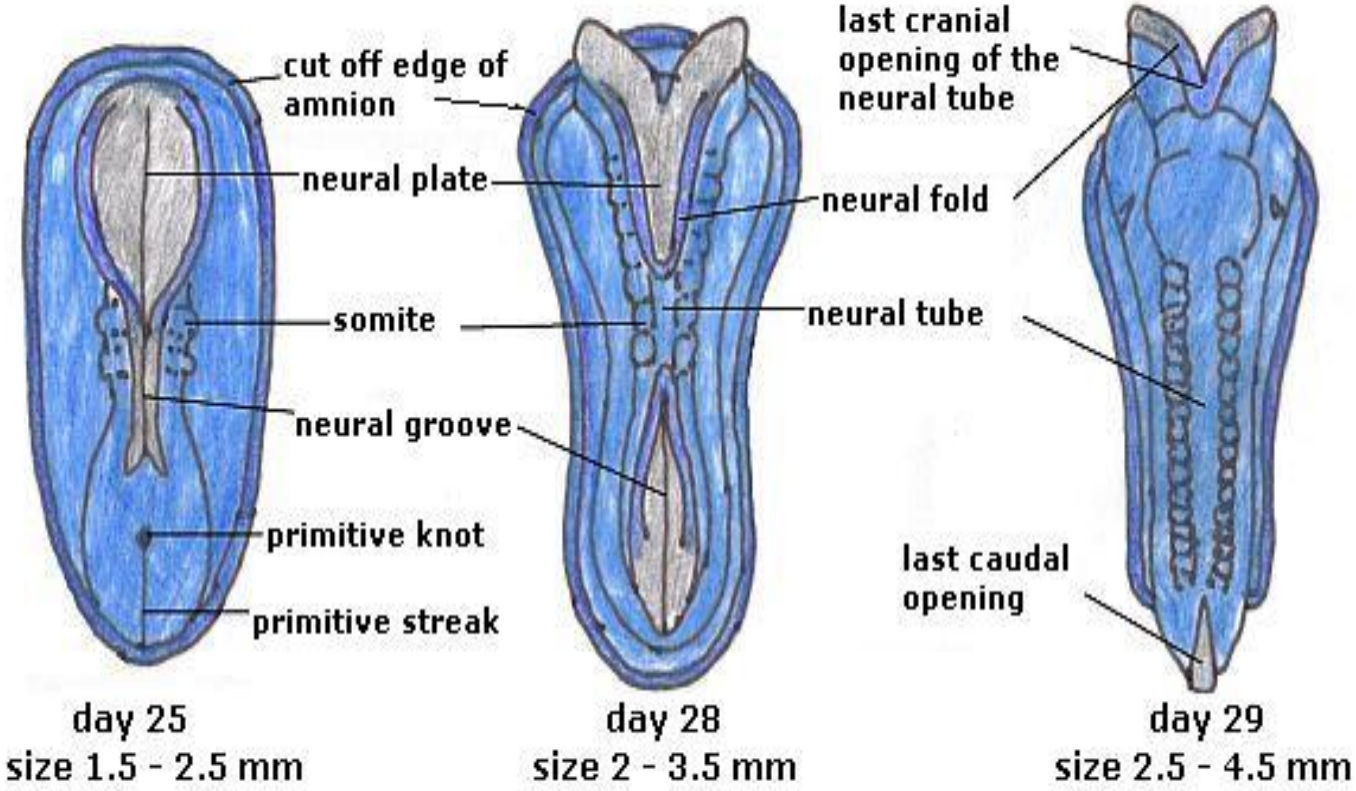
cut off edge of amnion
neural plate
somite
neural groove
primitive knot
primitive streak
last cranial opening of the neural tube
neural fold
neural tube
last caudal opening
day 25
size 1.5 - 2.5 mm
day 28
size 2 - 3.5 mm
day 29
size 2.5 - 4.5 mm

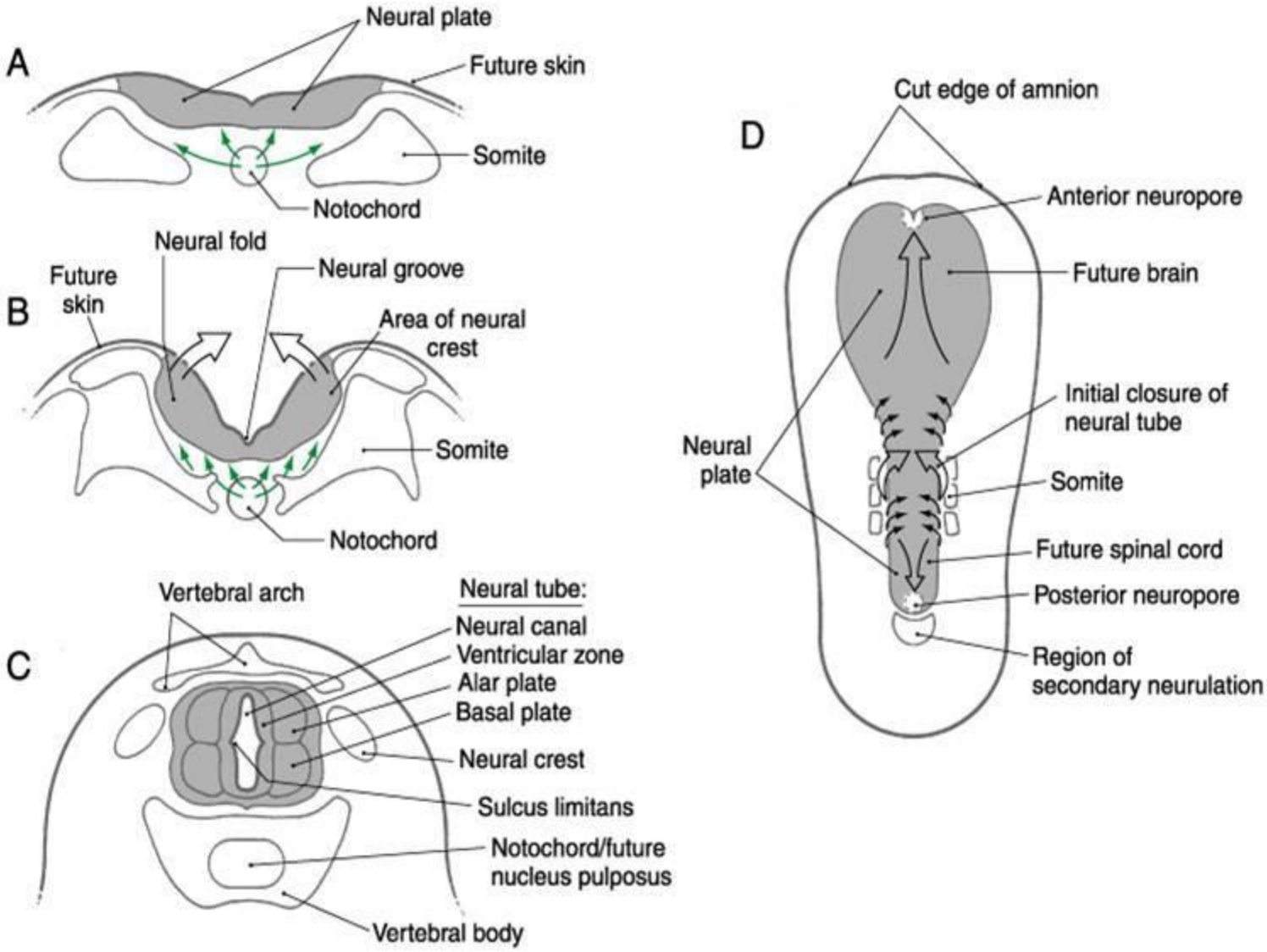
A
Neural plate
Future skin
Somite
Notochord
B
Neural fold
Future skin
Neural groove
Area of neural crest
Somite
Notochord
C
Vertebral arch
Neural tube:
Neural canal
Ventricular zone
Alar plate
Basal plate
Neural crest
Sulcus limitans
Notochord/future nucleus pulposus
Vertebral body
D
Cut edge of amnion
Anterior neuropore
Future brain
Initial closure of neural tube
Neural plate
Somite
Future spinal cord
Posterior neuropore
Region of secondary neurulation

Embryological Development

- CNS arises from ectoderm
- Neural tube

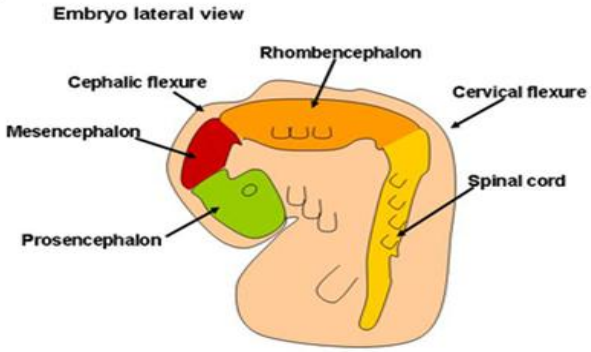

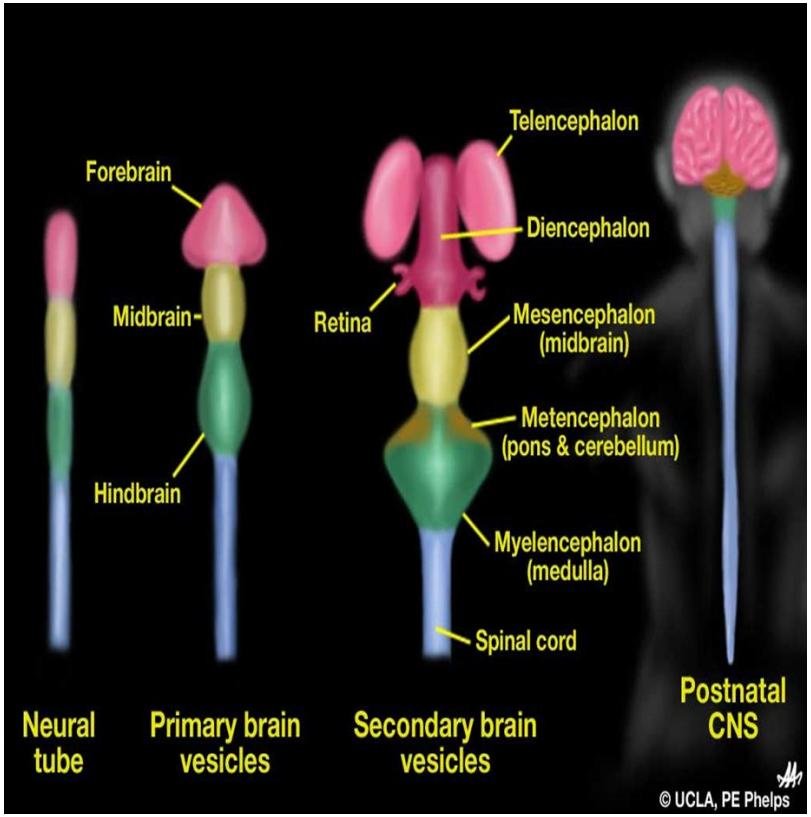

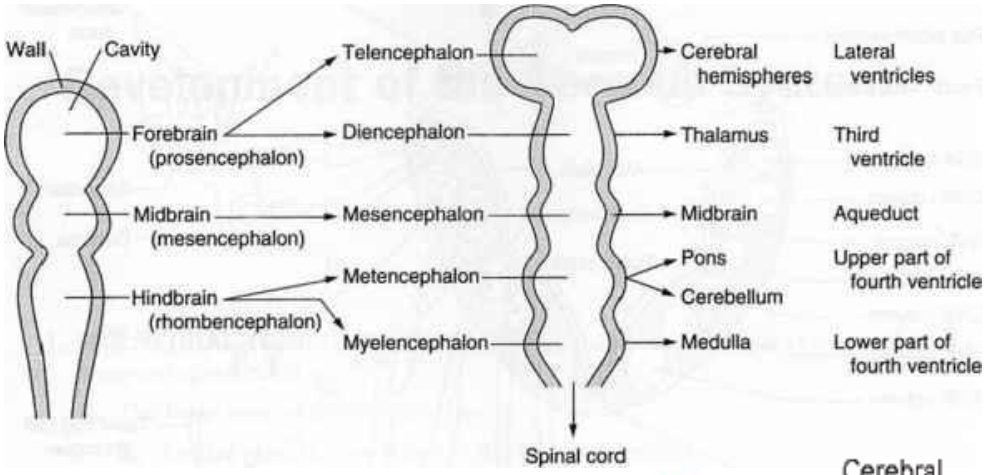

Embryological Development

- CNS arises from ectoderm
- Neural tube

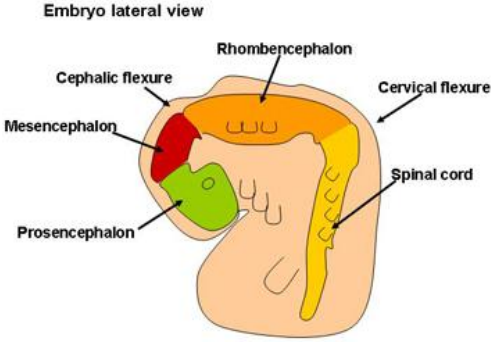

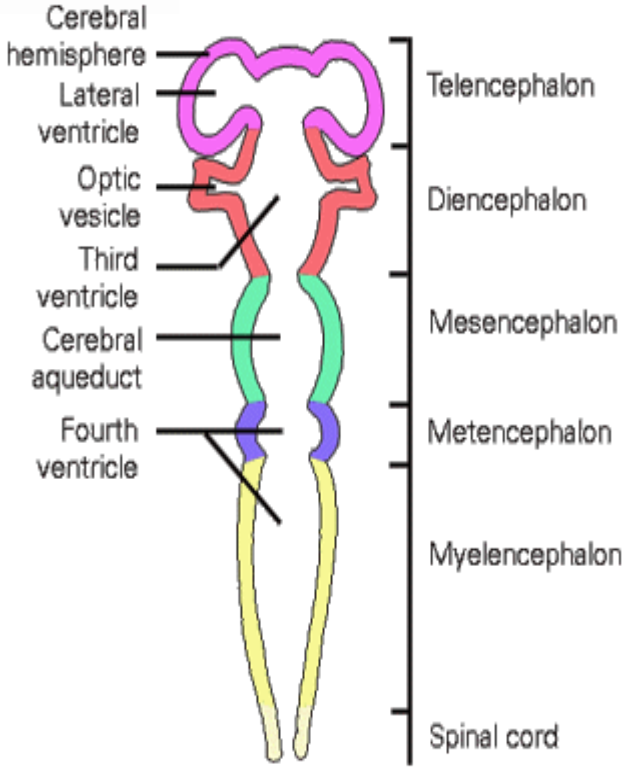

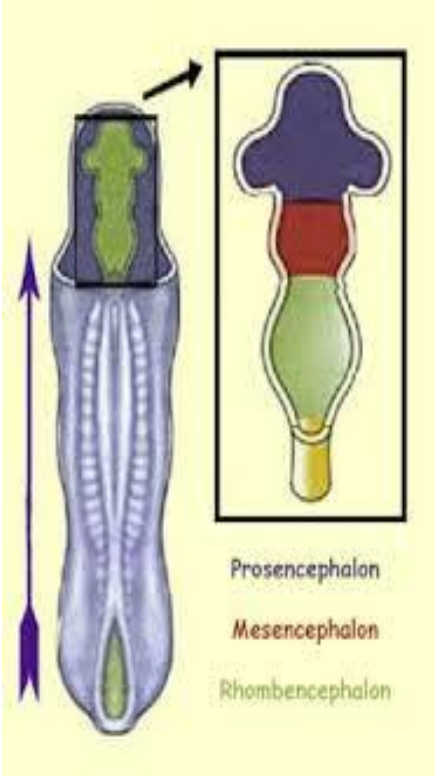

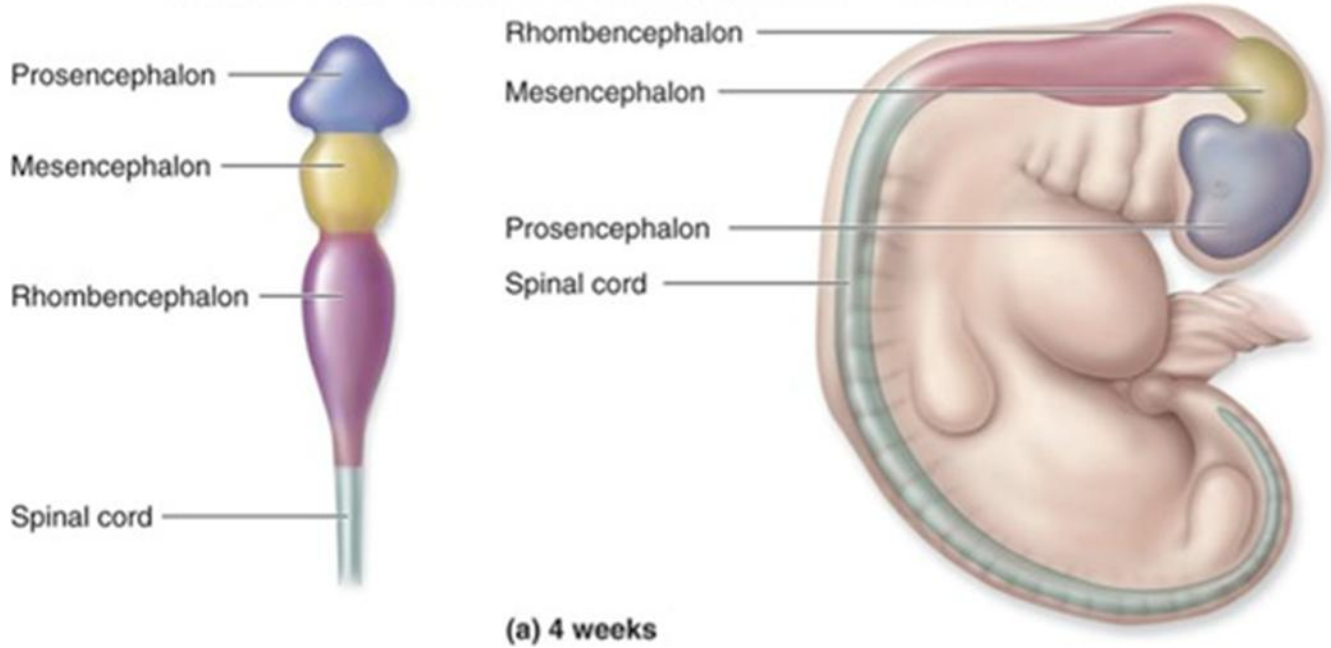

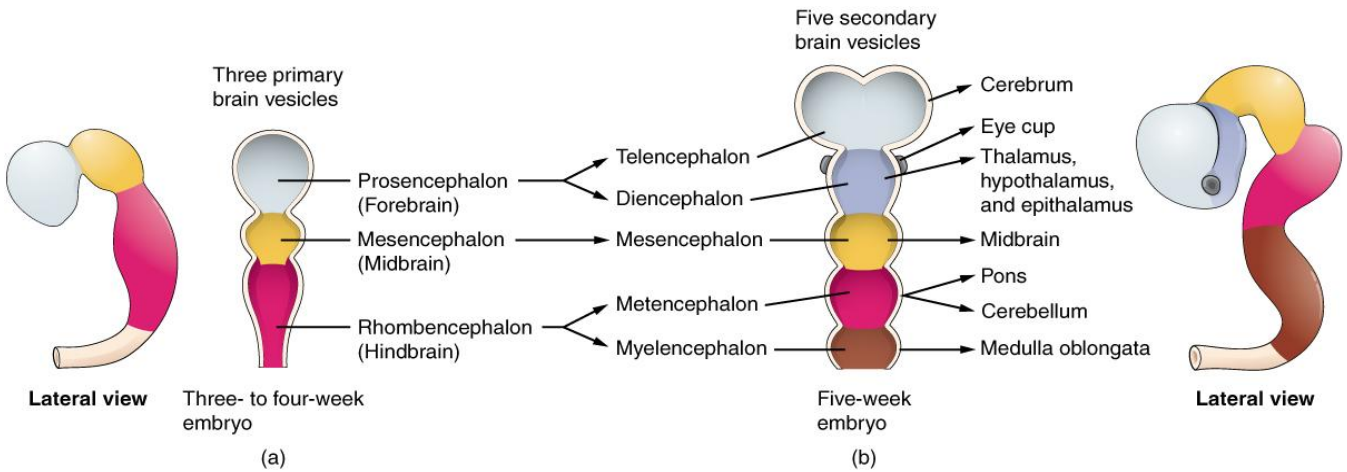

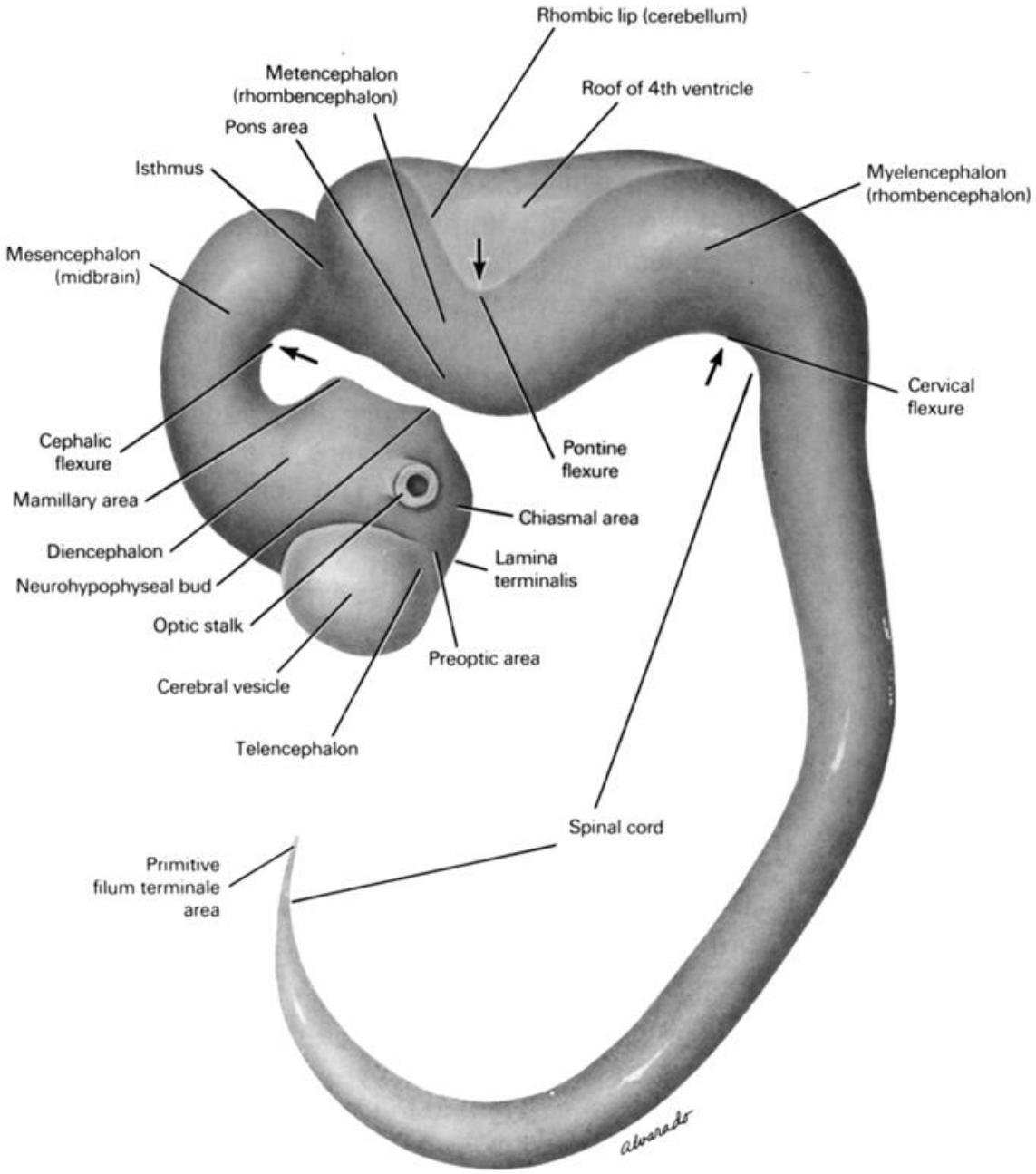
Rhombic lip (cerebellum)
Metencephalon
(rhombencephalon)
Roof of 4th ventricle
Pons area
Isthmus
Myelencephalon
(rhombencephalon)
Mesencephalon
(midbrain)
Cervical
flexure
Cephalic
flexure
Pontine
flexure
Mamillary area
Chiasmal area
Diencephalon
Lamina
terminalis
Neurohypophyseal bud
Optic stalk
Preoptic area
Cerebral vesicle
Telencephalon
Spinal cord
Primitive
filum terminale
area

Embryonic		Adult
Prosencephalon	I. Telencephalon	Cerebrum
	II. Diencephalon	Thalamus, hypothalamus, epithalamus
Mesencephalon	III. Mesencephalon	Mesencephalon
Rhombencephalon	IV. Metencephalon	Pons, cerebellum
	V. Myelencephalon	Medulla oblongata

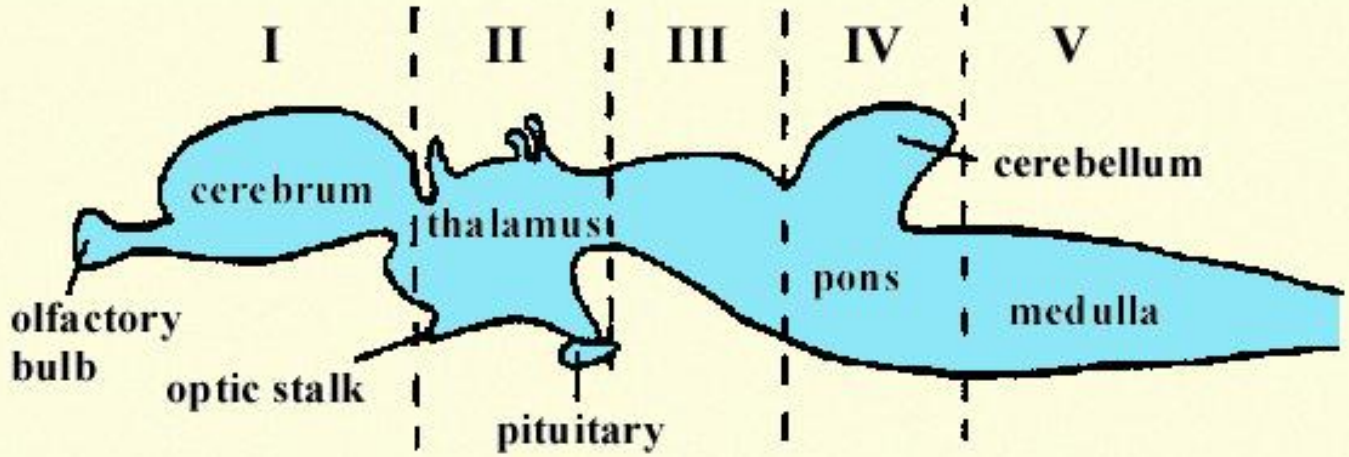

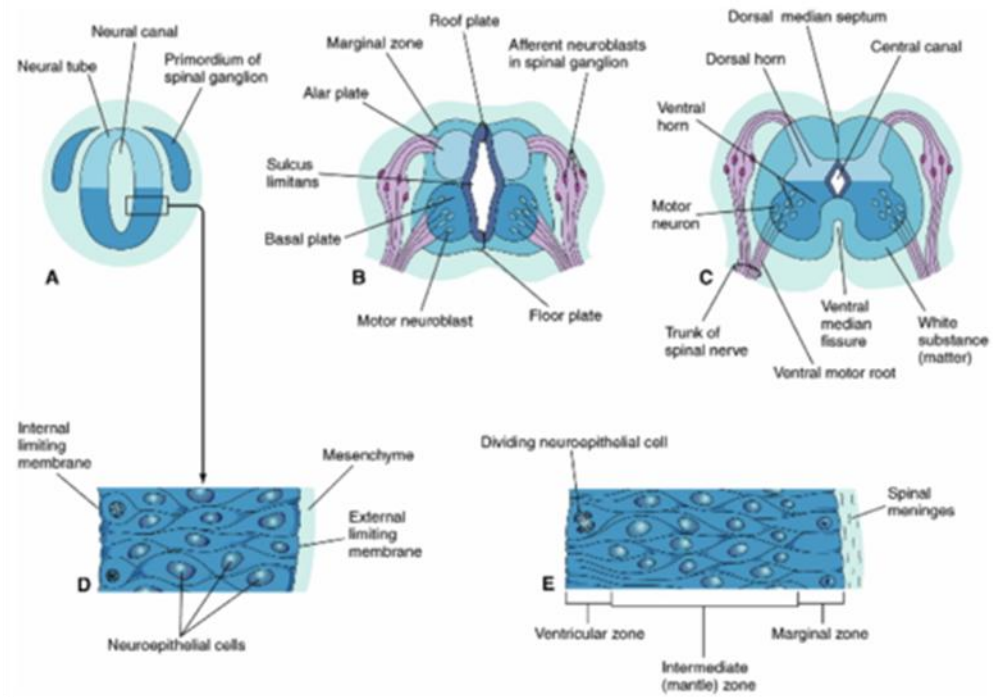
Neural canal
Neural tube
Primordium of spinal ganglion
A
Roof plate
Marginal zone
Afferent neuroblasts in spinal ganglion
Alar plate
Sulcus limitans
Basal plate
B
Motor neuroblast
Floor plate
Dorsal median septum
Dorsal horn
Central canal
Ventral horn
Motor neuron
C
Trunk of spinal nerve
Ventral median fissure
White substance (matter)
Ventral motor root
Internal limiting membrane
Mesenchyme
External limiting membrane
D
Neuroepithelial cells
Dividing neuroepithelial cell
Spinal meninges
E
Ventricular zone
Marginal zone
Intermediate (mantle) zone

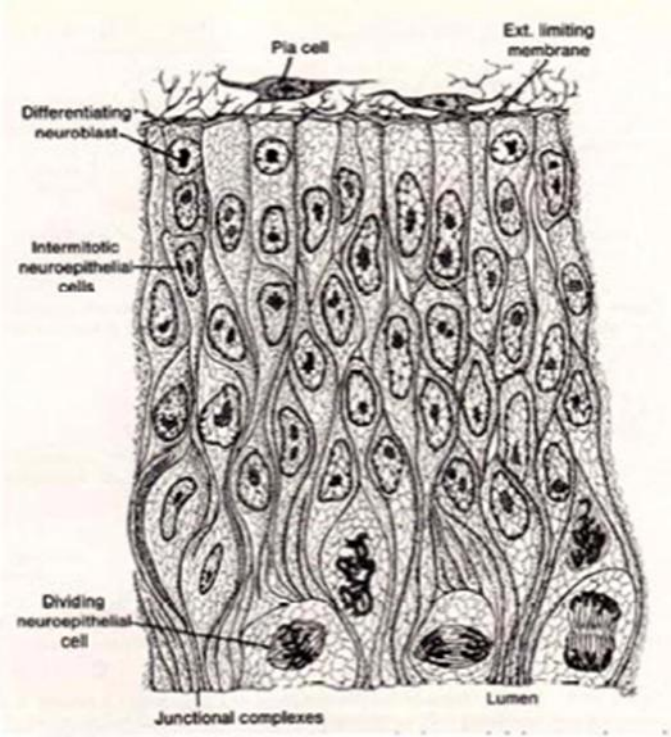
Pia cell
Ext. limiting membrane
Differentiating neuroblast
Intermitotic neuroepithelial cells
Dividing neuroepithelial cell
Junctional complexes
Lumen

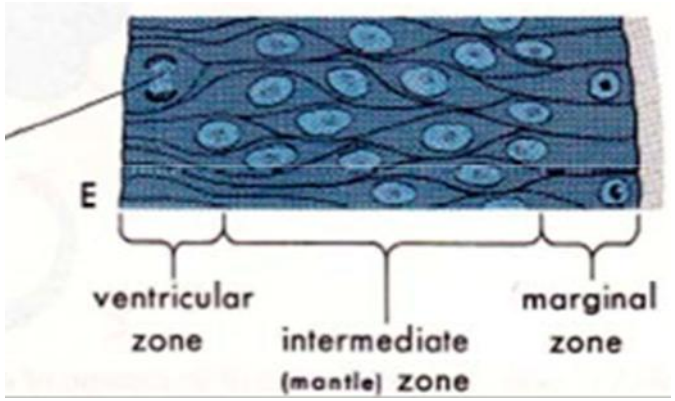
E
ventricular zone
intermediate (mantle) zone
marginal zone

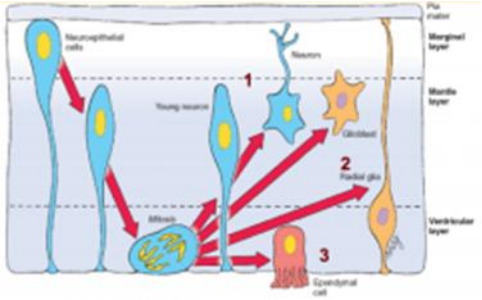
1
2
3

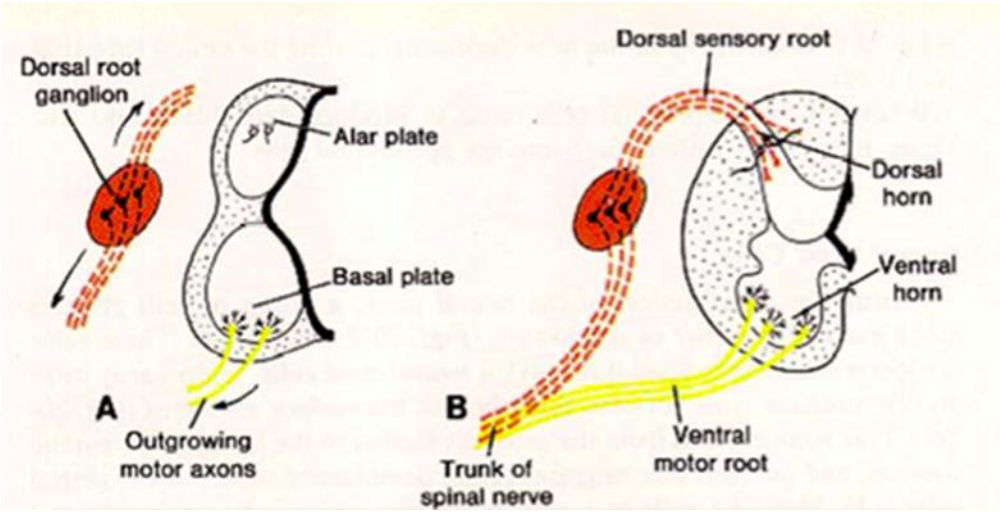

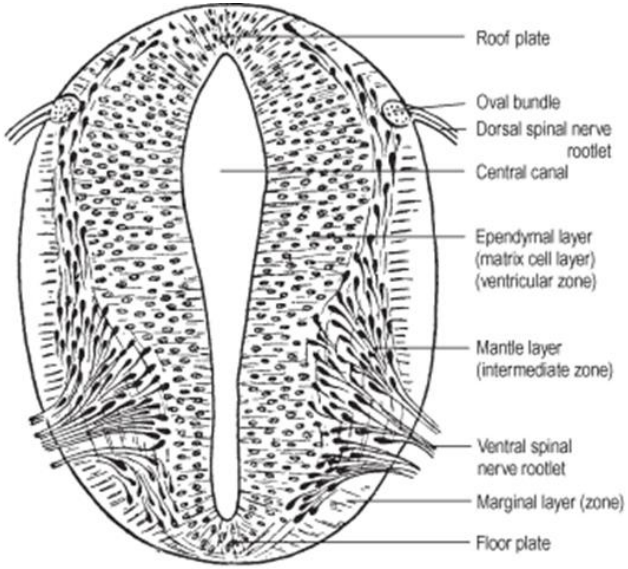

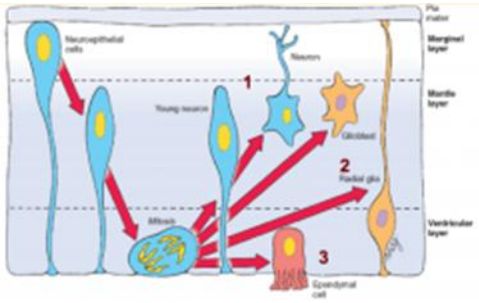

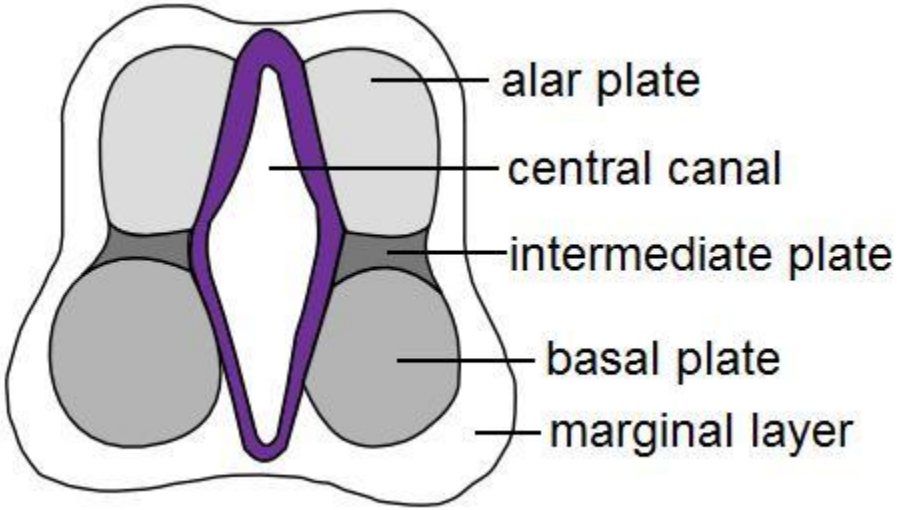

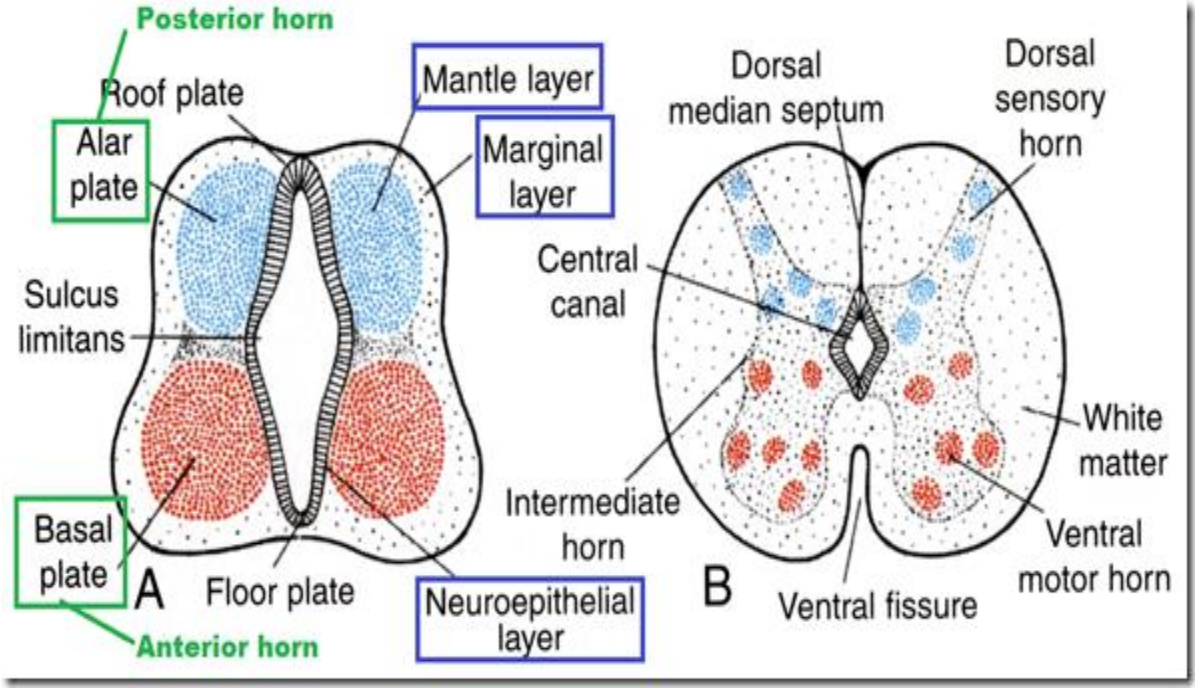
Posterior horn
Roof plate
Mantle layer
Alar plate
Marginal layer
Sulcus limitans
Basal plate
A
Floor plate
Neuroepithelial layer
Anterior horn
Dorsal median septum
Dorsal sensory horn
Central canal
White matter
Intermediate horn
Ventral motor horn
B
Ventral fissure

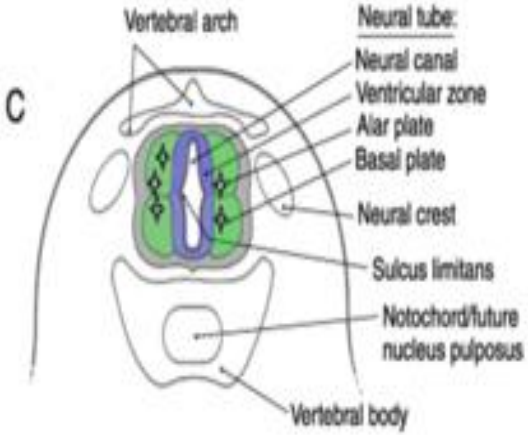
C
Vertebral arch
Neural tube:
Neural canal
Ventricular zone
Alar plate
Basal plate
Neural crest
Sulcus limitans
Notochord/future nucleus pulposus
Vertebral body

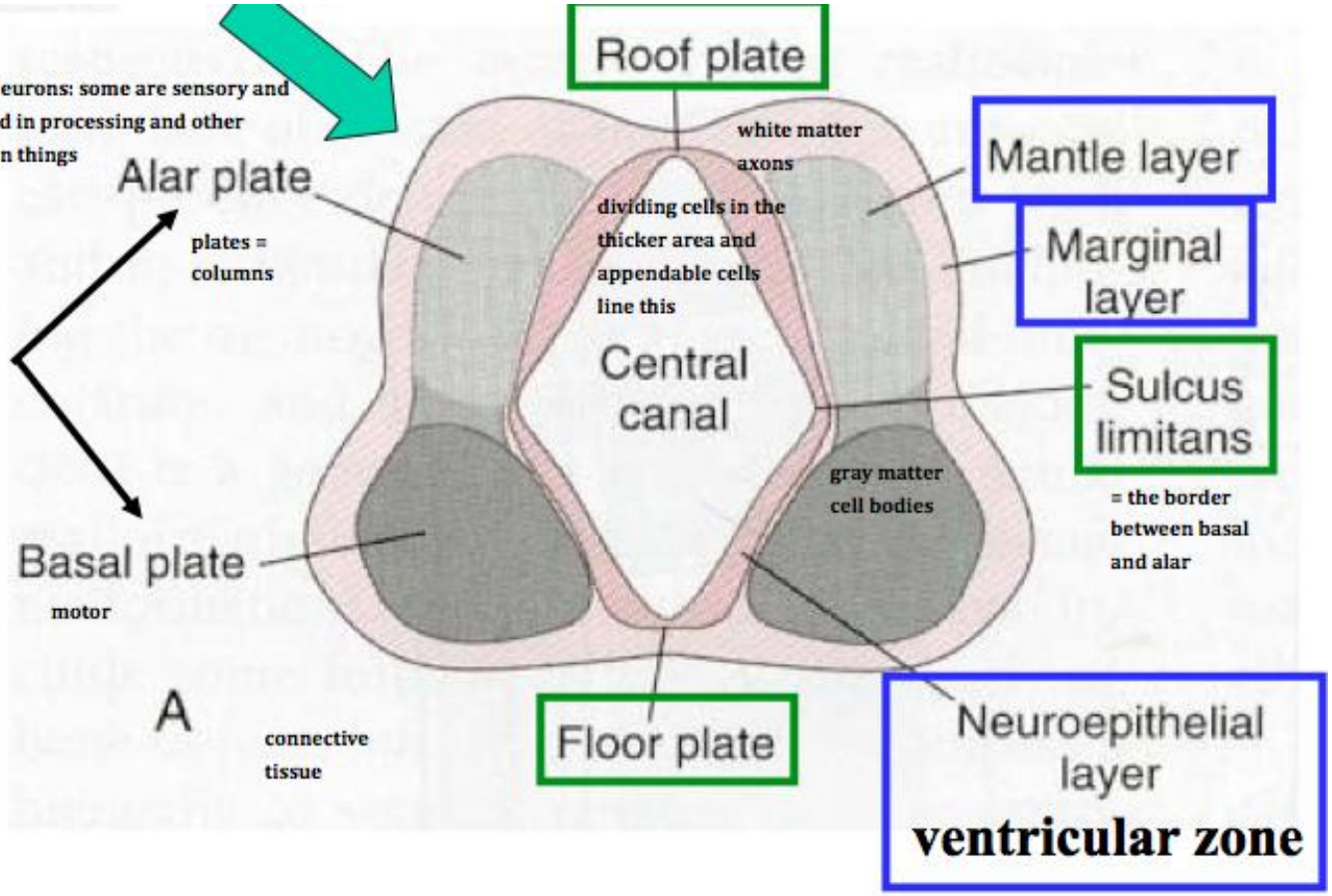
Roof plate
association neurons: some are sensory and some involved in processing and other higher neuron things
Alar plate
plates = columns
white matter axons
Mantle layer
dividing cells in the thicker area and appendable cells line this
Marginal layer
mantle layer divides into
Central canal
Sulcus limitans
gray matter cell bodies
= the border between basal and alar
Basal plate
motor
A
connective tissue
Floor plate
Neuroepithelial layer
ventricular zone

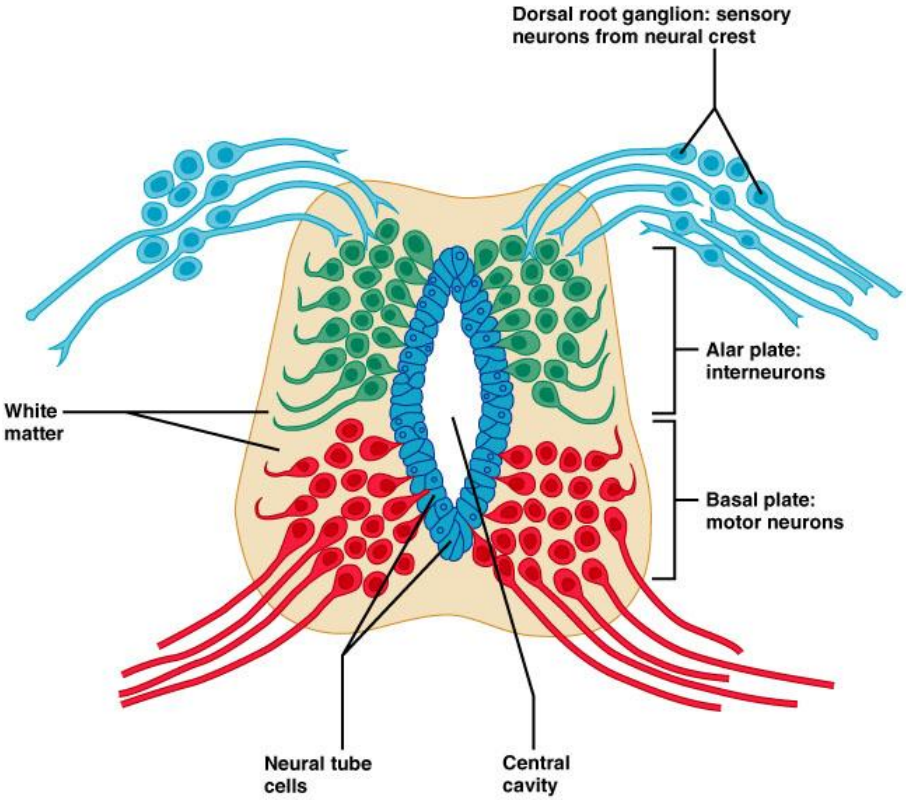

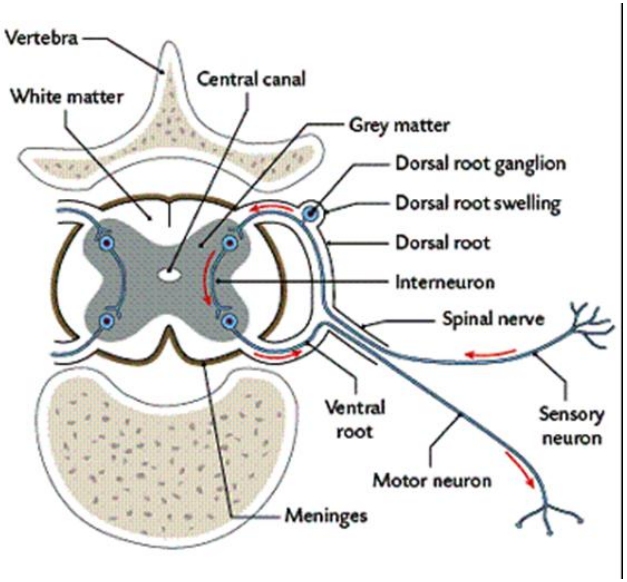

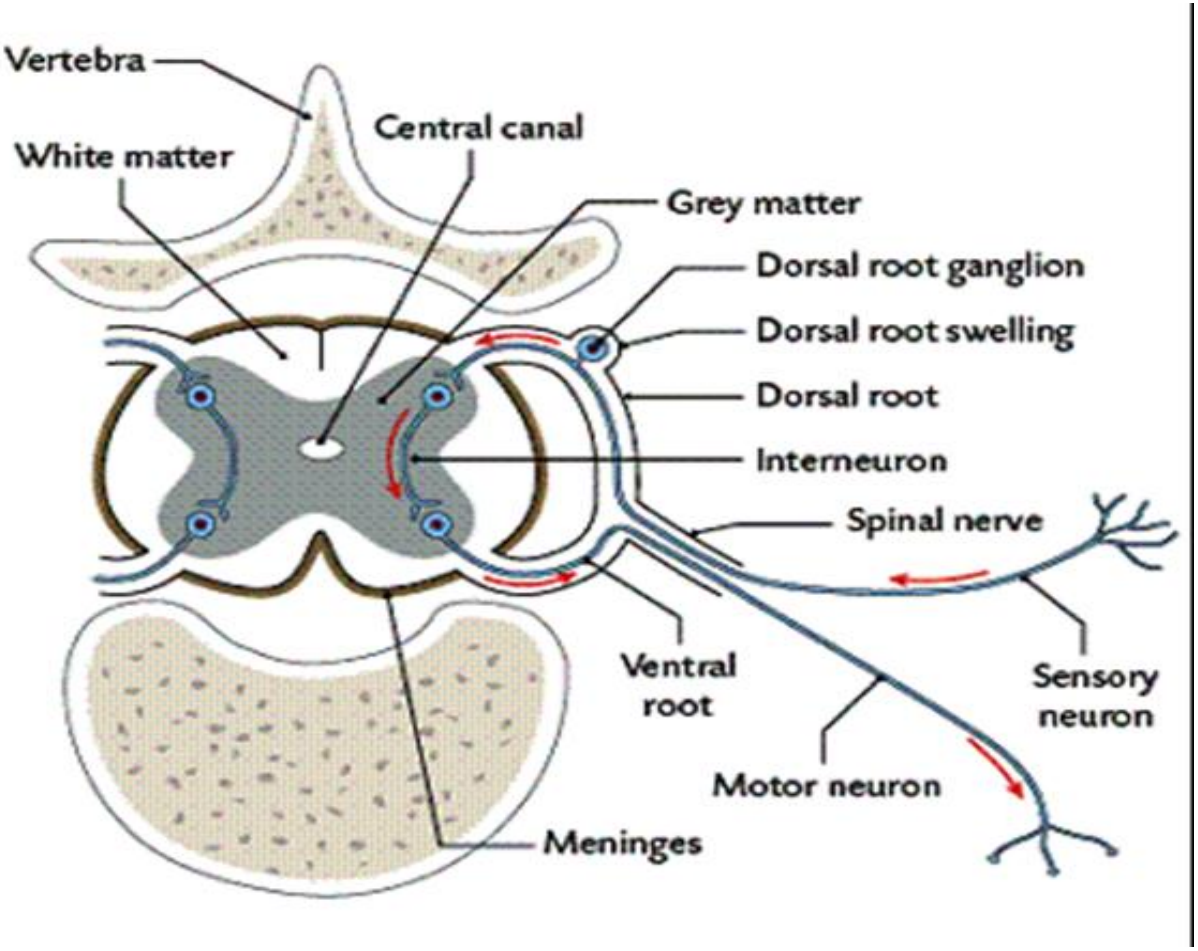
Vertebra
Central canal
White matter
Grey matter
Dorsal root ganglion
Dorsal root swelling
Dorsal root
Interneuron
Spinal nerve
Ventral root
Sensory neuron
Motor neuron
Meninges

Embryonic Development of NS

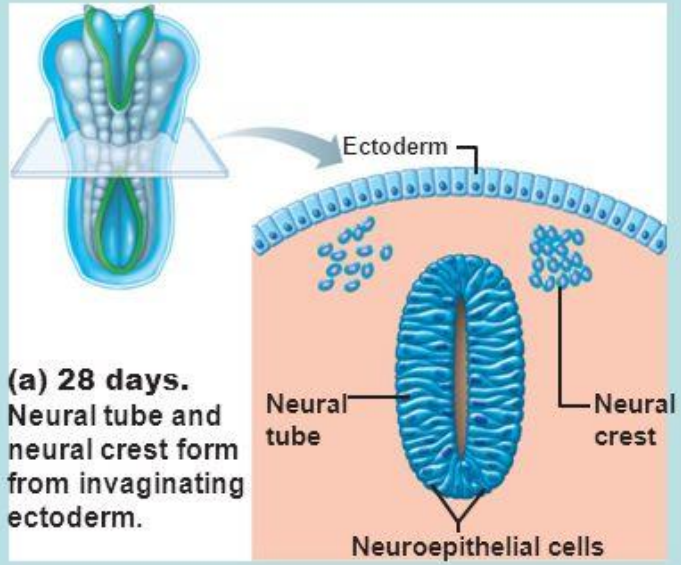

(a) 28 days. Neural tube and neural crest form from invaginating ectoderm.

(b) Week 5. Neuroepithelial cells of the neural tube divide and migrate externally to become neuroblasts and neuroglia.

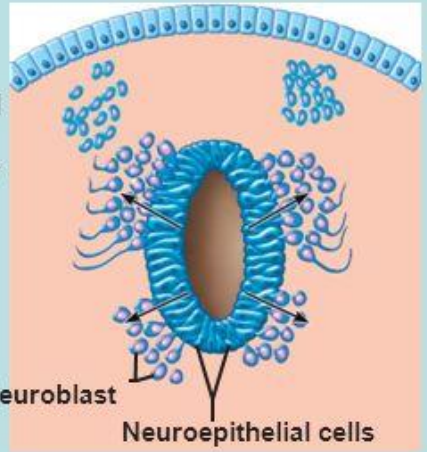

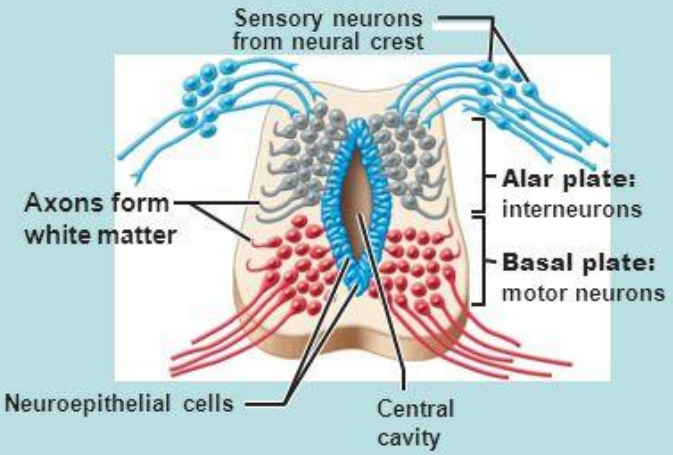

(c) Week 6. Neural crest cells form the sensory neurons.

Dorsal neuroblasts form the alar plate (future interneurons). Long axons extending from the interneurons form the white matter.

Ventral neuroblasts form the basal plate (future motor neurons).

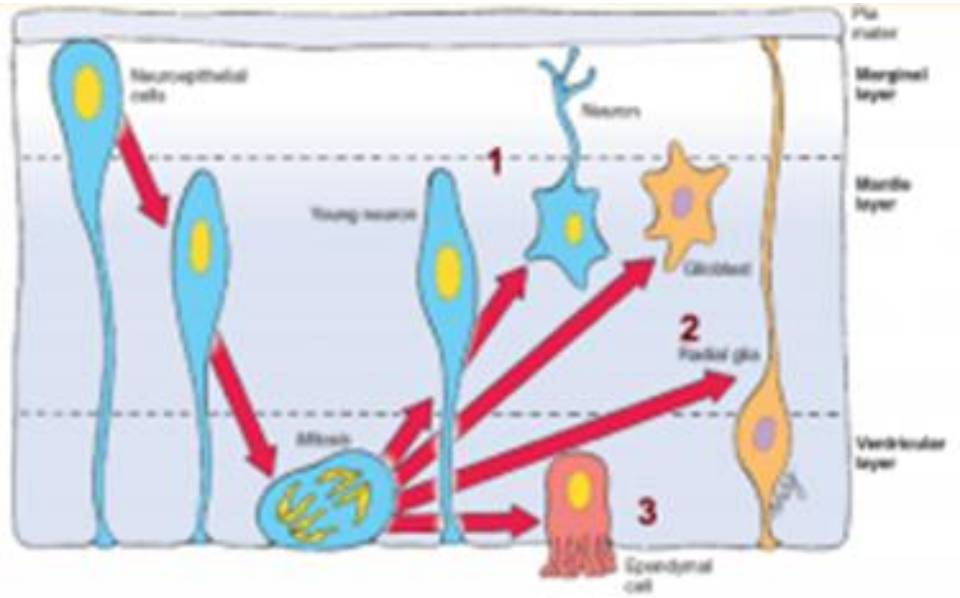
Pia mater
Marginal layer
Mantle layer
Ventricular layer
Neuroepithelial cells
Neuron
Young neuron
Glioblast
Radial glia
Mitosis
Ependymal cell
1
2
3

التمايز النسيجي لخلايا الأنبوب العصبي

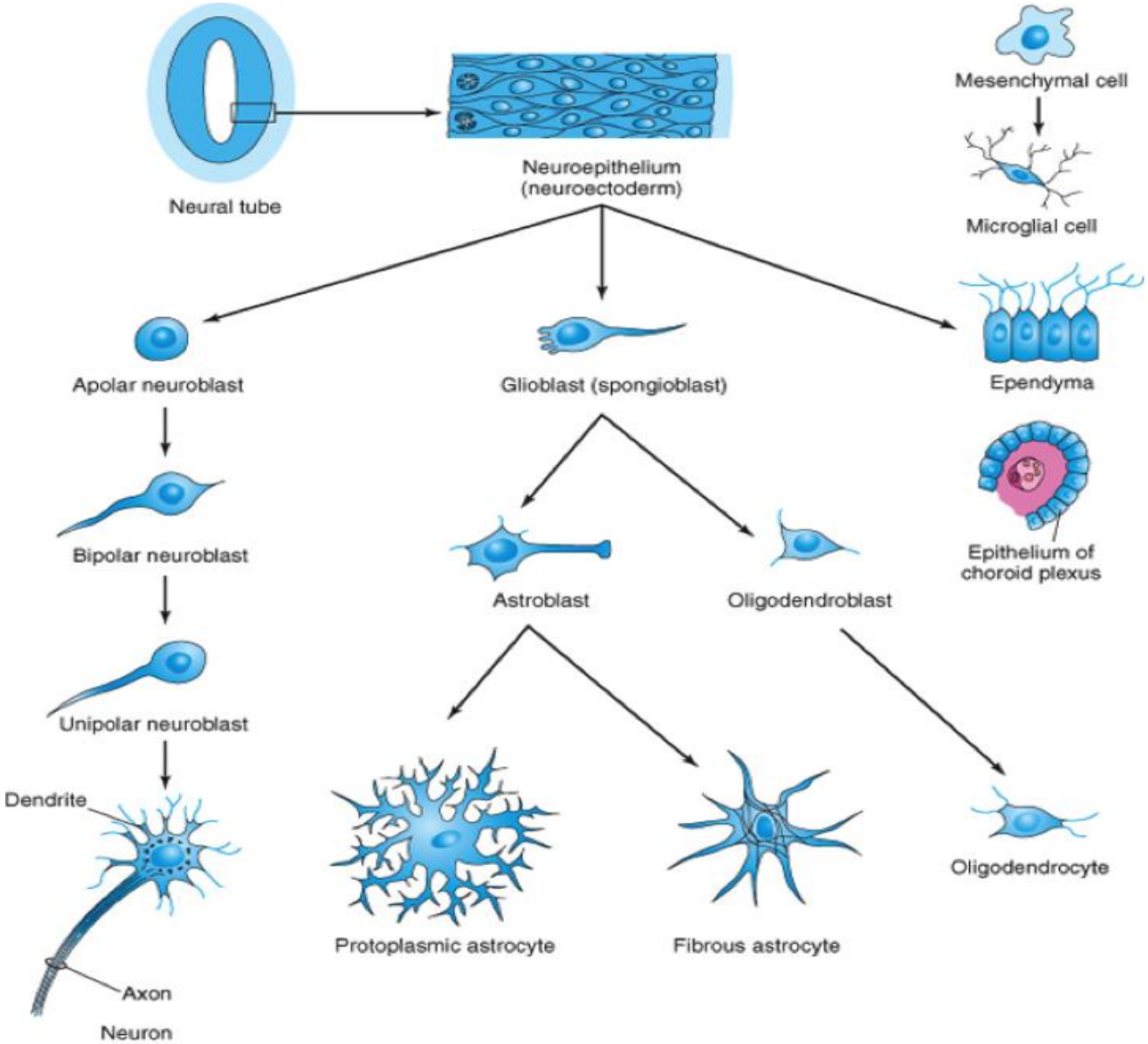

تكوين السحايا الشوكية

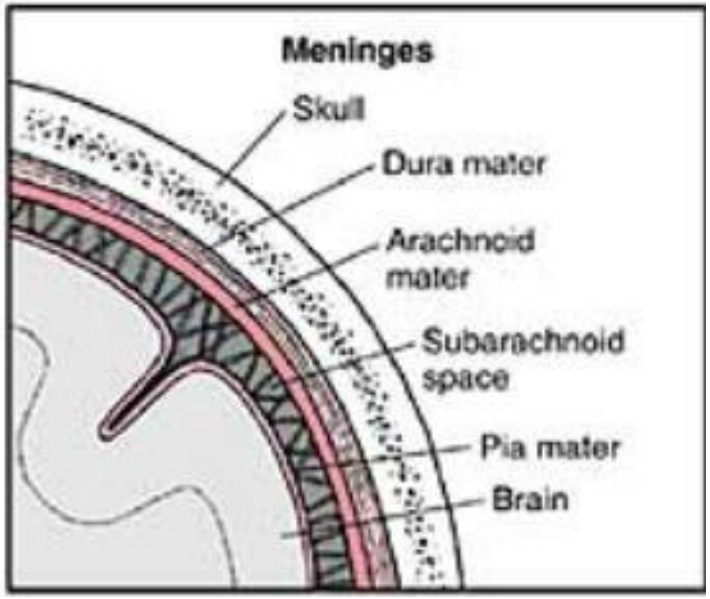

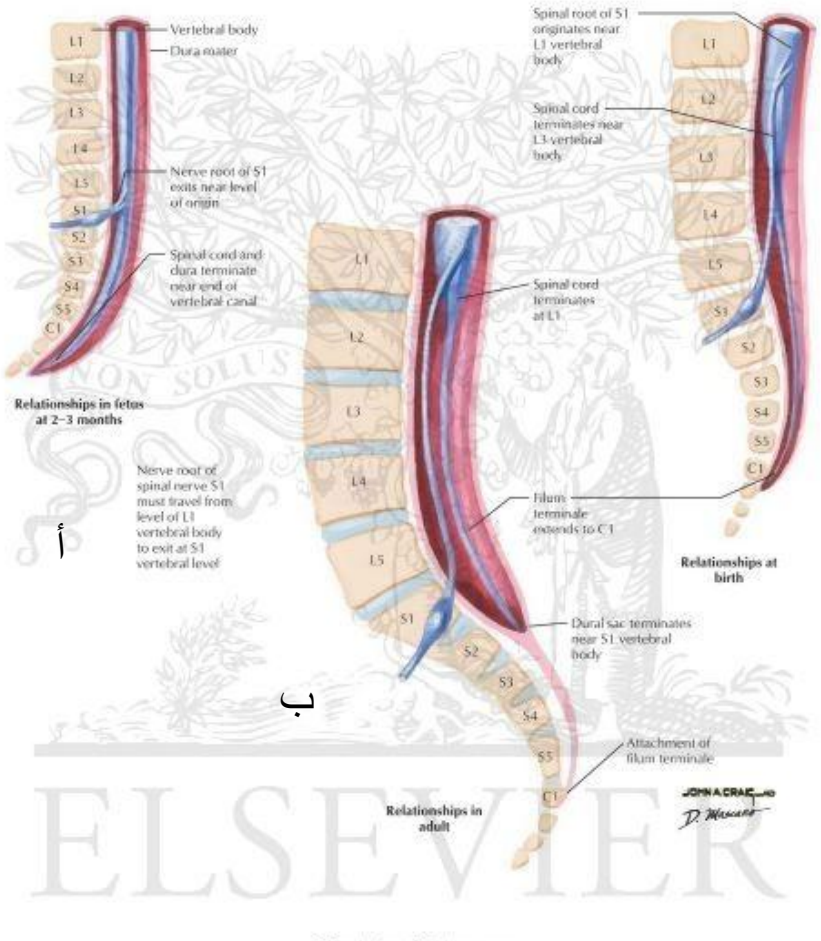
Vertebral body
Dura mater
Nerve root of S1 exits near level of origin
Spinal cord and dura terminate near end of vertebral canal
Relationships in fetus at 2–3 months
Nerve root of spinal nerve S1 must travel from level of L1 vertebral body to exit at S1 vertebral level
أ
Spinal root of S1 originates near L3 vertebral body
Spinal cord terminates near L3 vertebral body
Spinal cord terminates at L1
Filum terminale extends to C1
Relationships at birth
Dural sac terminates near S1 vertebral body
ب
Attachment of filum terminale
Relationships in adult
ج
© Elsevier, Inc. - Netterimages.com
© ELSEVIER, INC. – NETTERIMAGES.COM

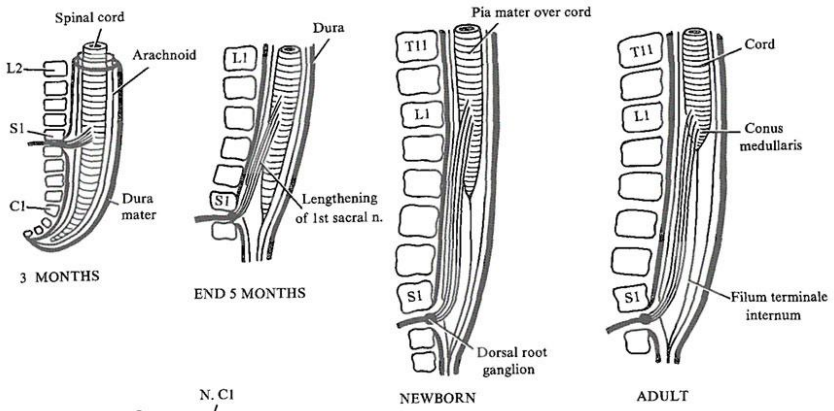
Spinal cord
Arachnoid
Dura mater
3 MONTHS
Dura
Lengthening of 1st sacral n.
END 5 MONTHS
Pia mater over cord
Dorsal root ganglion
NEWBORN
Cord
Conus medullaris
Filum terminale internum
ADULT

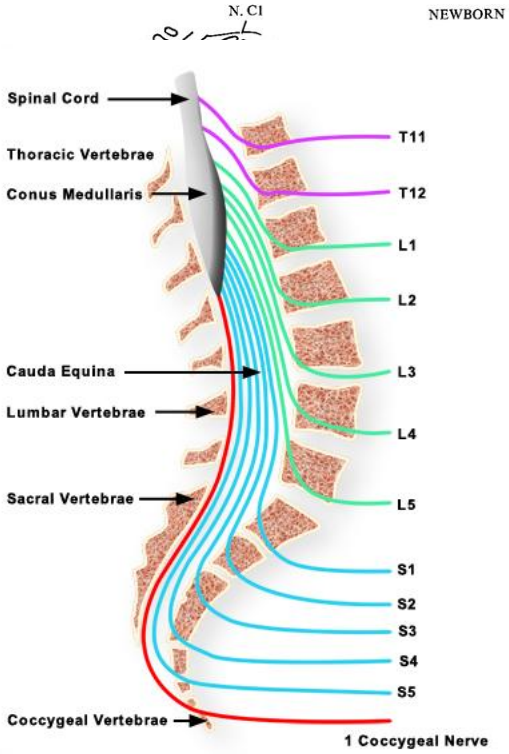
N. C1
Spinal Cord
Thoracic Vertebrae
Conus Medullaris
Cauda Equina
Lumbar Vertebrae
Sacral Vertebrae
Coccygeal Vertebrae
T11
T12
L1
L2
L3
L4
L5
S1
S2
S3
S4
S5
1 Coccygeal Nerve
© www.apparelyzed.com

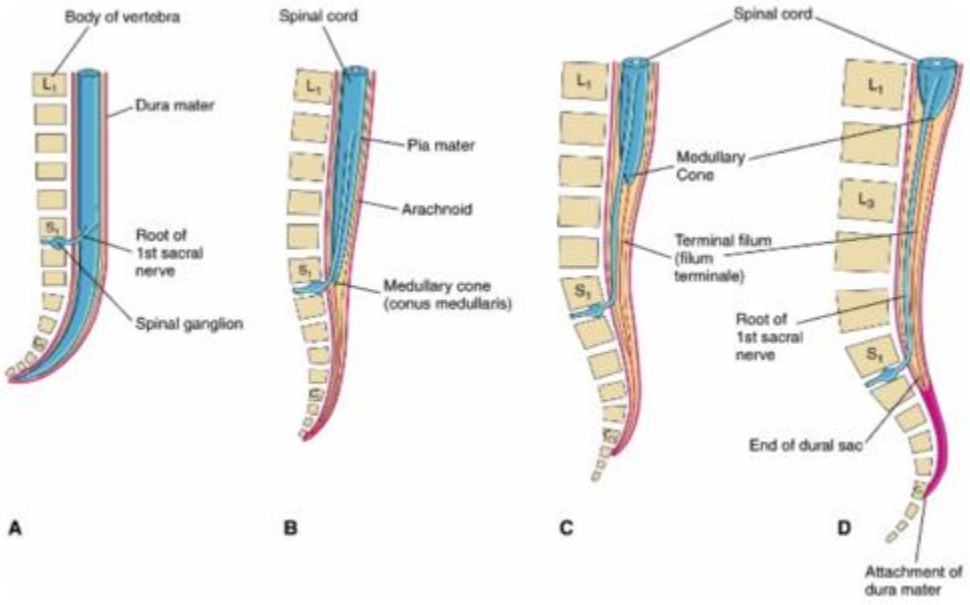
Body of vertebra
Dura mater
Root of 1st sacral nerve
Spinal ganglion
A
Spinal cord
Pia mater
Arachnoid
Medullary cone (conus medullaris)
B
Spinal cord
Medullary Cone
Terminal filum (filum terminale)
C
Root of 1st sacral nerve
End of dural sac
Attachment of dura mater
D

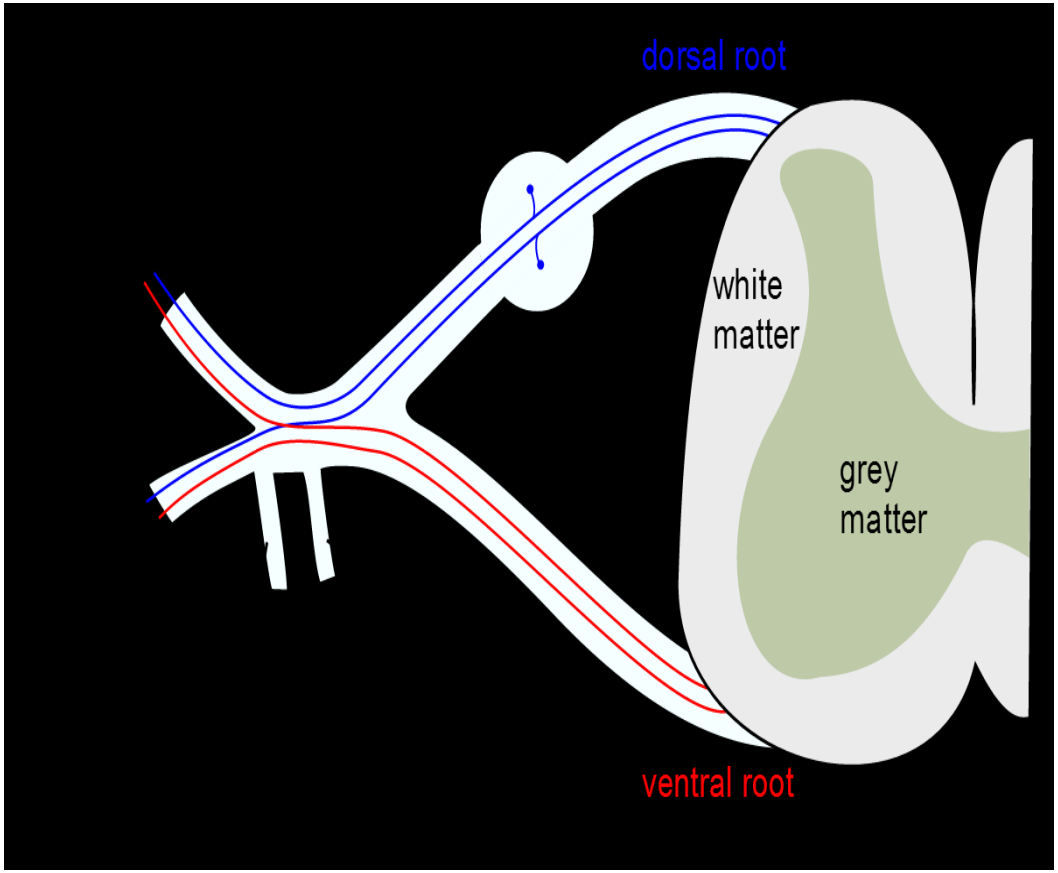
dorsal root
white matter
grey matter
ventral root

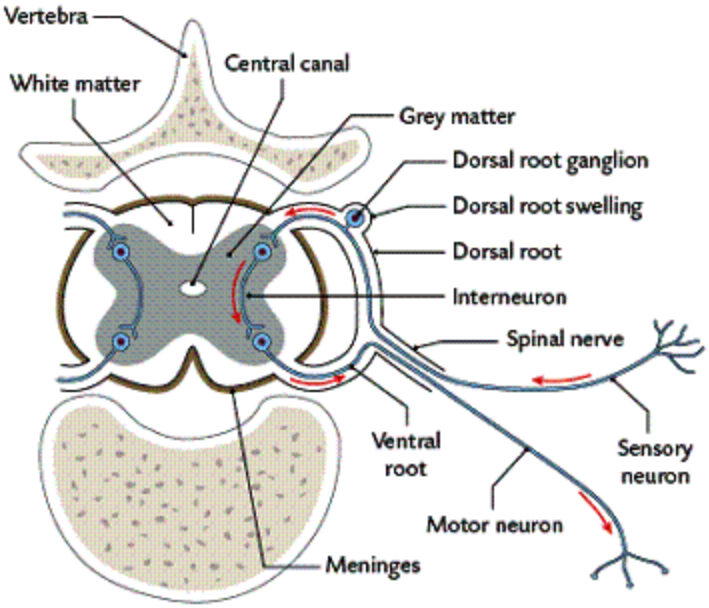
Vertebra
Central canal
White matter
Grey matter
Dorsal root ganglion
Dorsal root swelling
Dorsal root
Interneuron
Spinal nerve
Ventral root
Sensory neuron
Motor neuron
Meninges

التغيرات في سطح المخ :

.

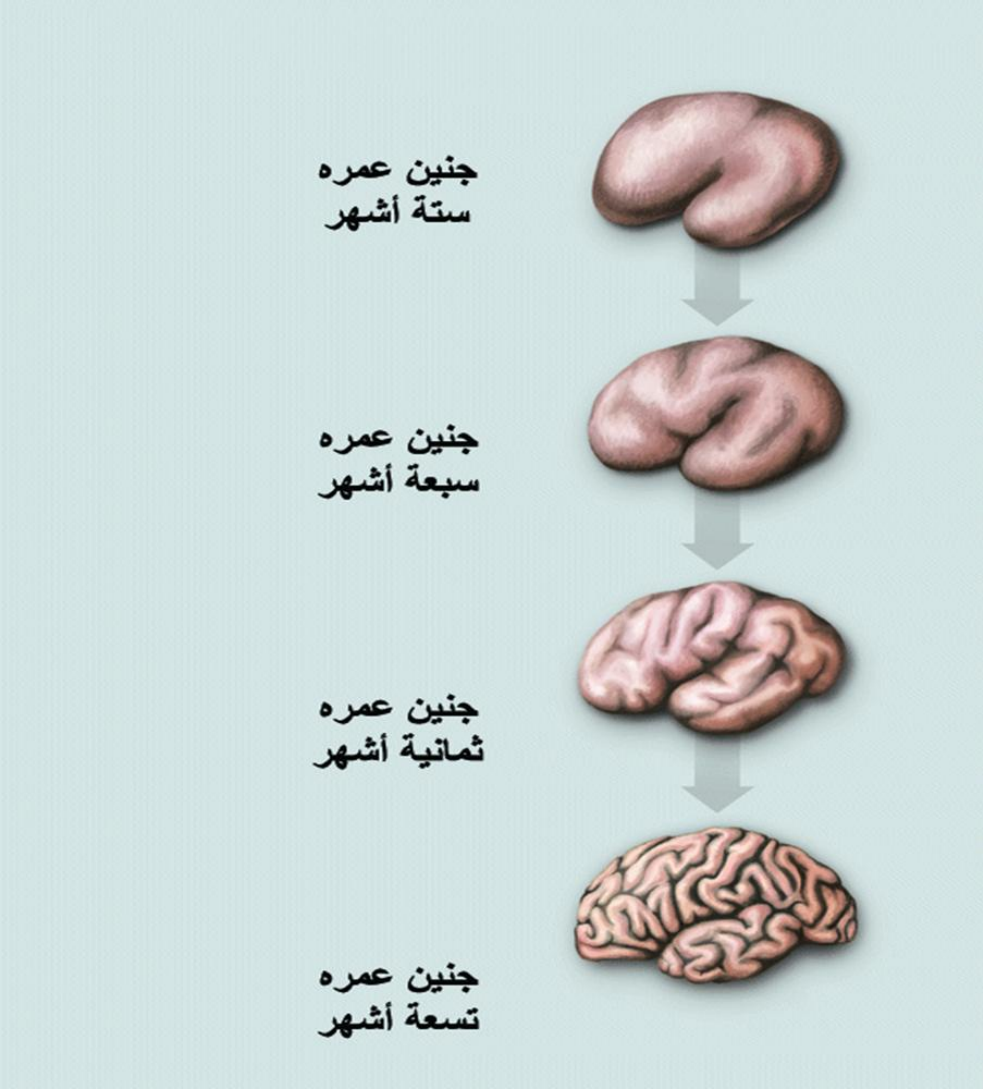

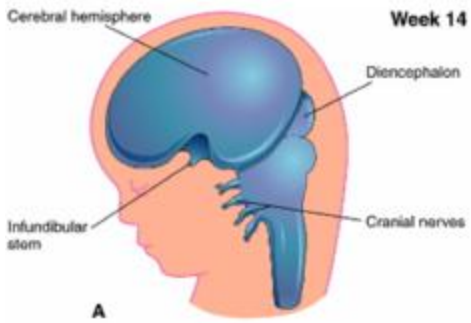
Week 14
Cerebral hemisphere
Diencephalon
Infundibular stem
Cranial nerves
A

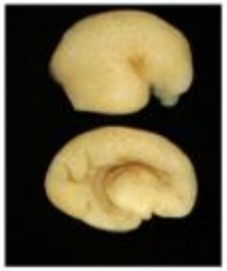

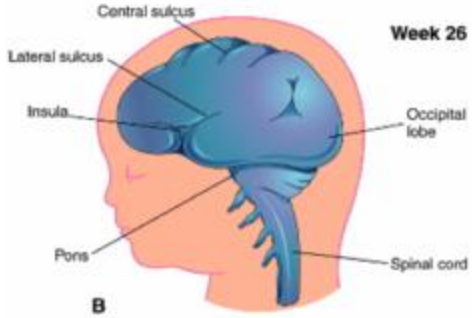
Week 26
Central sulcus
Lateral sulcus
Insula
Occipital lobe
Pons
Spinal cord
B

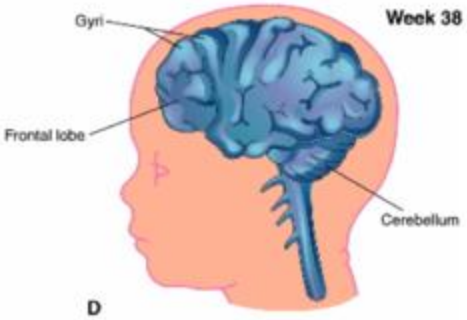
Week 38
Gyri
Frontal lobe
Cerebellum
D

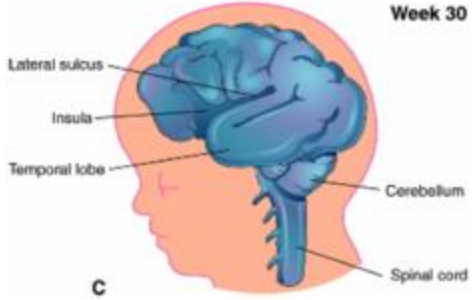
Week 30
Lateral sulcus
Insula
Temporal lobe
Cerebellum
Spinal cord
C

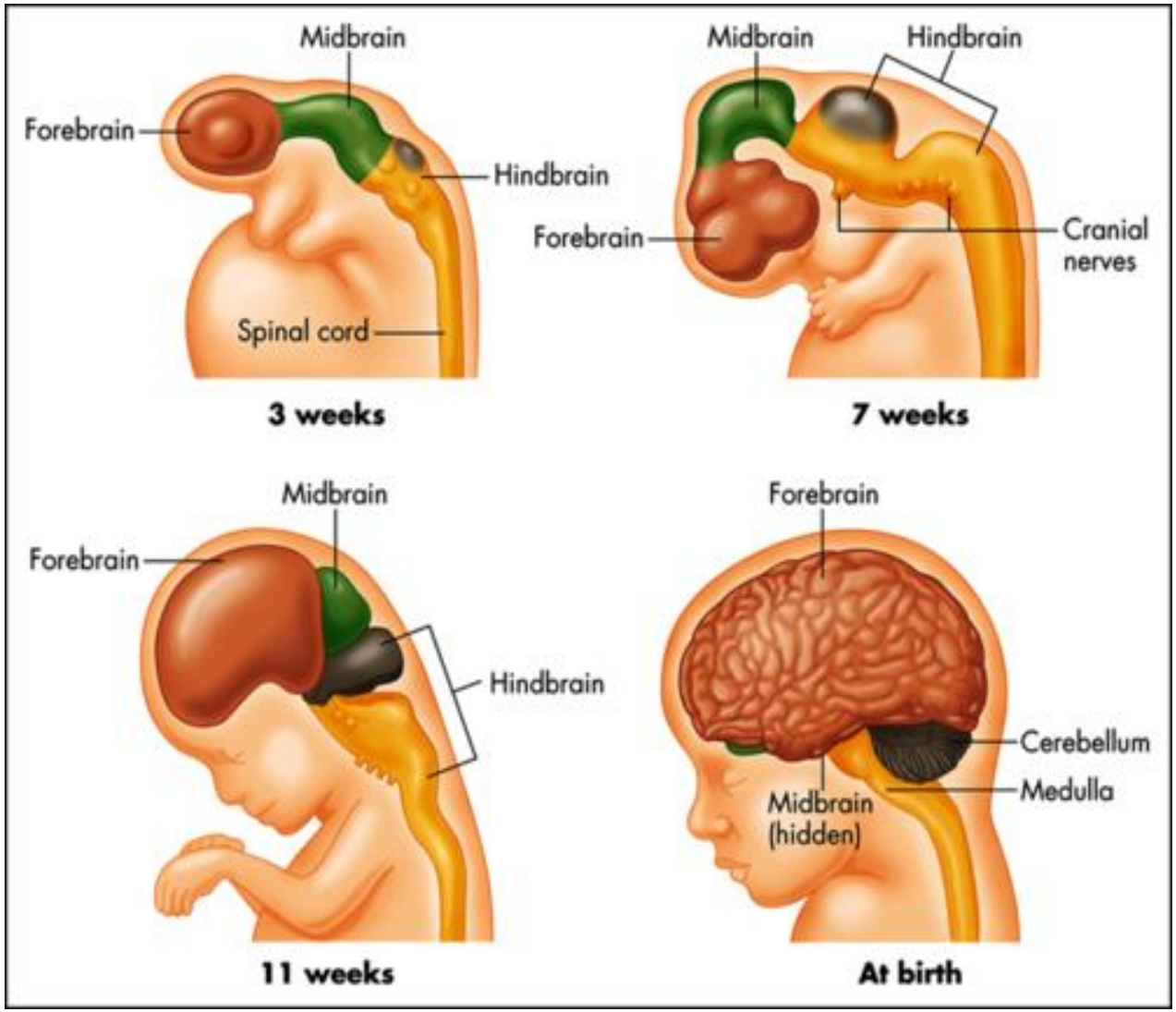
Midbrain
Forebrain
Hindbrain
Spinal cord
3 weeks
Midbrain
Hindbrain
Forebrain
Cranial nerves
7 weeks
Midbrain
Forebrain
Hindbrain
11 weeks
Forebrain
Cerebellum
Medulla
Midbrain (hidden)
At birth

Fetal Development of Human Brain (1)

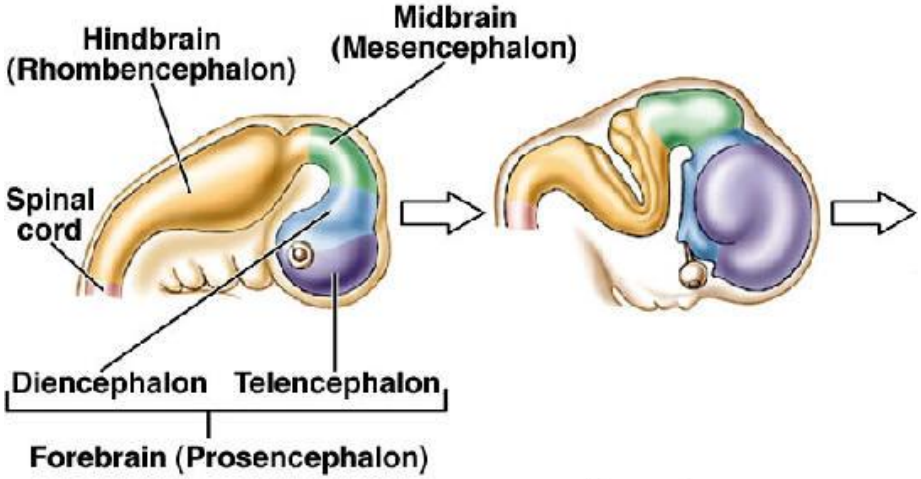

5 weeks

8 weeks

Fetal Development of Human Brain (2)

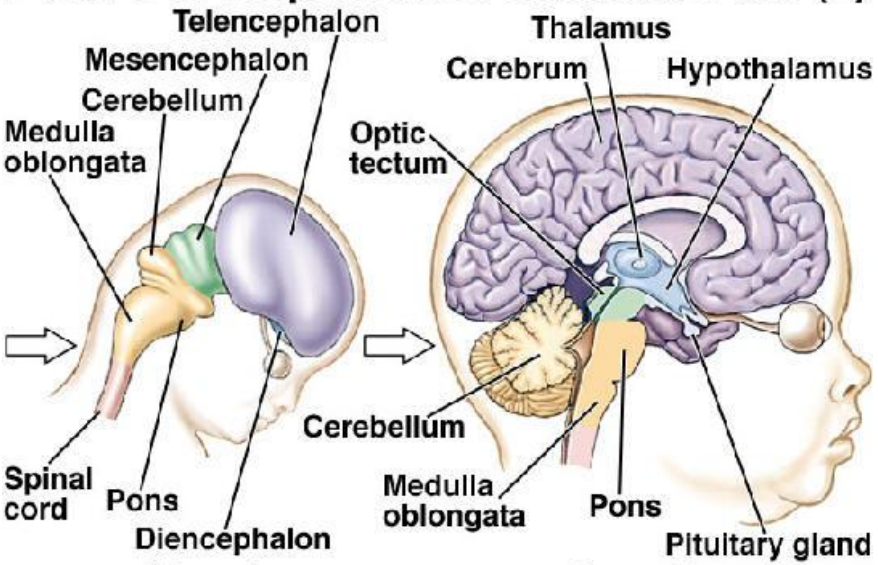

11 weeks

9 months

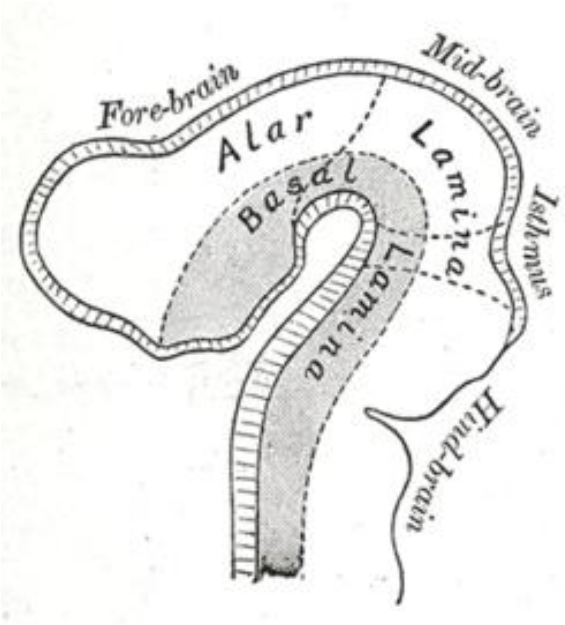
Fore-brain
Mid-brain
Alar
Basal
Lamina
Lamina
Isthmus
Hind-brain

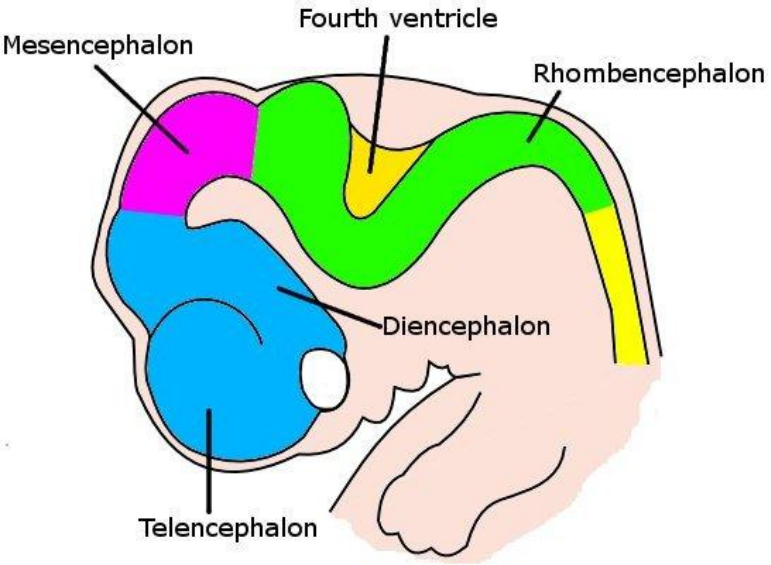
Fourth ventricle
Mesencephalon
Rhombencephalon
Diencephalon
Telencephalon

Medulla

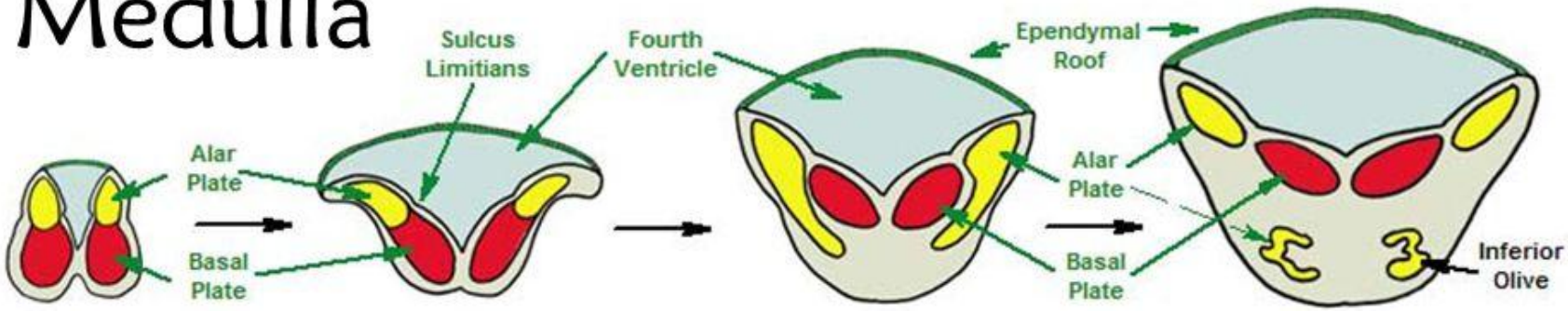

- The expansion of fourth ventricle moved the alar plates laterally
- The neuroblasts at the basal plates form the motor nuclei of the CN IX, X, XI and XII
- The neuroblasts of the alar plates form the sensory nuclei of the CN V, VIII, IX and X, the gracile and cuneate nuclei and the olivary nuclei

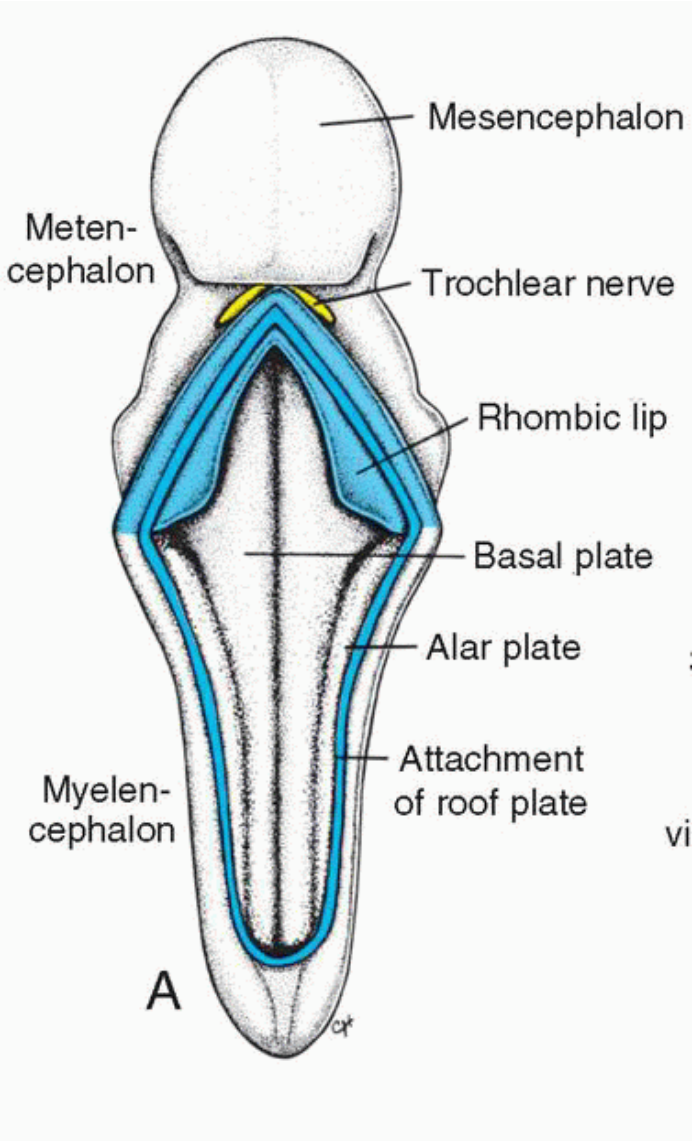
Mesencephalon
Meten-
cephalon
Trochlear nerve
Rhombic lip
Basal plate
Alar plate
Attachment
of roof plate
Myelen-
cephalon
A

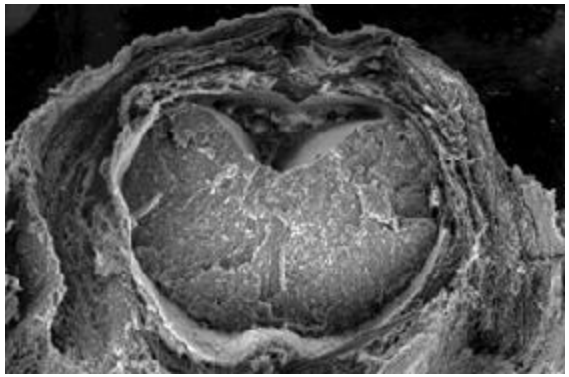

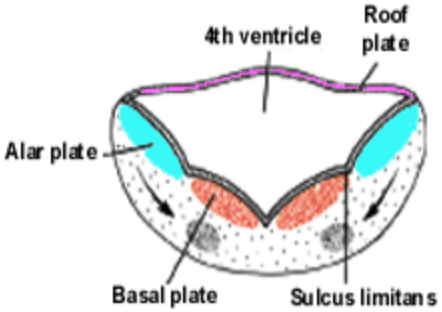
4th ventricle
Roof
plate
Alar plate
Basal plate
Sulcus limitans

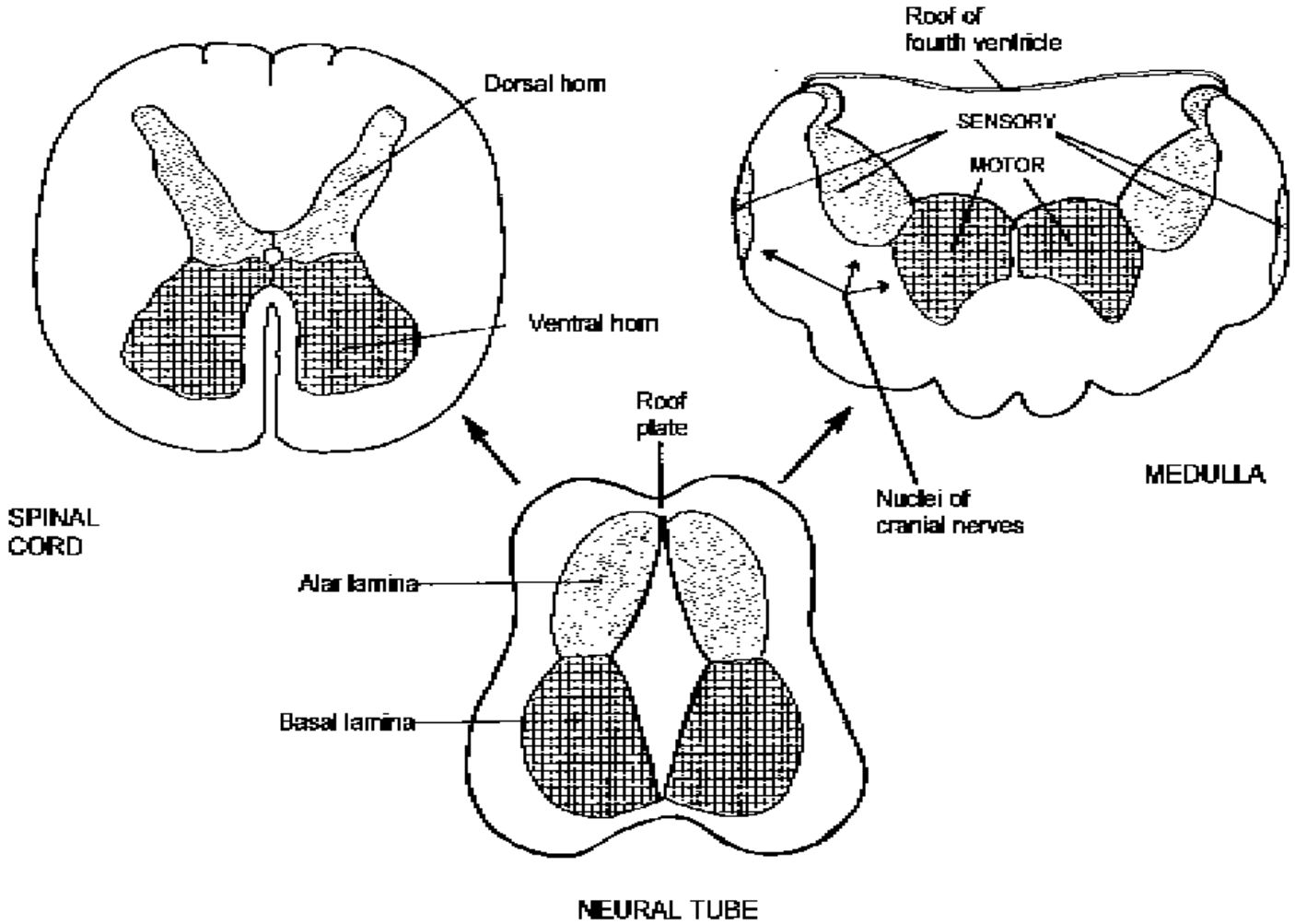

Fig. 21. Diagrams to show why sites of termination of primary sensory axons are situated dorsally in the spinal cord and laterally in the medulla.

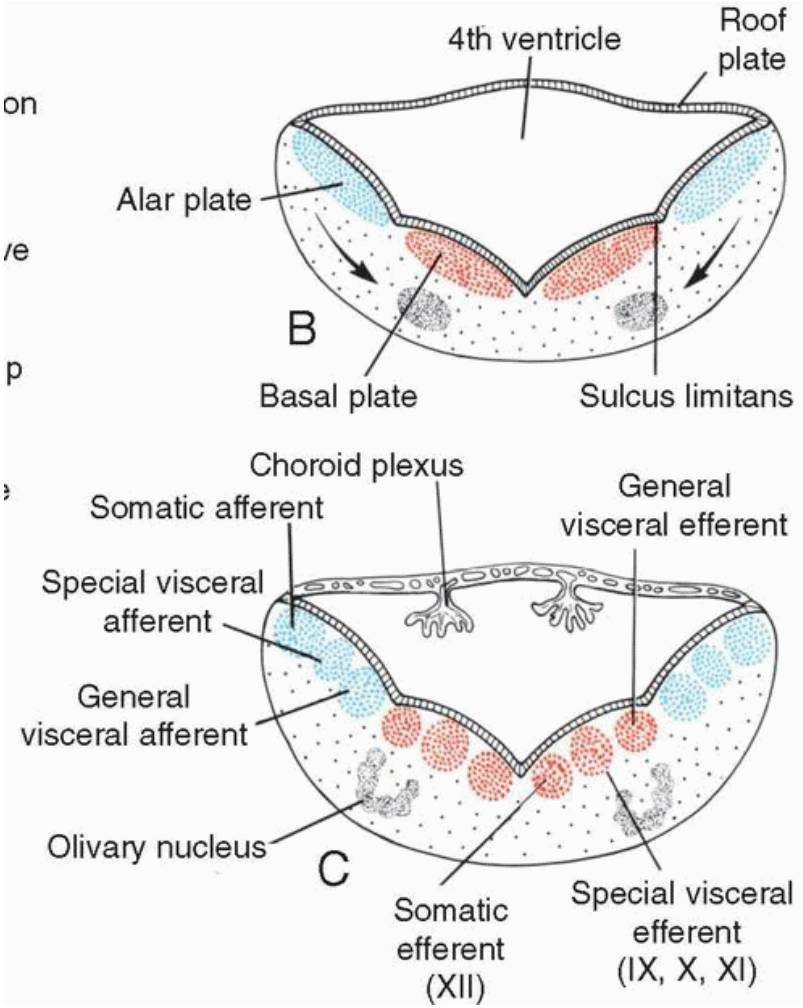
4th ventricle
Roof plate
Alar plate
B
Basal plate
Sulcus limitans
Choroid plexus
Somatic afferent
General visceral efferent
Special visceral afferent
General visceral afferent
Olivary nucleus
C
Somatic efferent (XII)
Special visceral efferent (IX, X, XI)

Development of the myelencephalon

- Alar plate develops into 4 sensory tracts:
  - Olivary nucleus (cerebellar input)
  - Somatic afferent (general sensation from the face, via CN V, external ear, auditory meatus, and eardrum via CN IX, X)
  - Special visceral afferent (taste, CN IX, X)
  - General visceral afferent (autonomic input, CN IX, X)
- Basal plate develops into 3 motor tracts:
  - General visceral efferent (autonomic output, CN IX, X)
  - Special visceral efferent (innervation of pharyngeal arch muscles of the larynx & pharynx, CN IX, X, XI) – aka "branchiomotor"
  - Somatic efferent (innervation of skeletal muscles of the tongue, CN XII)

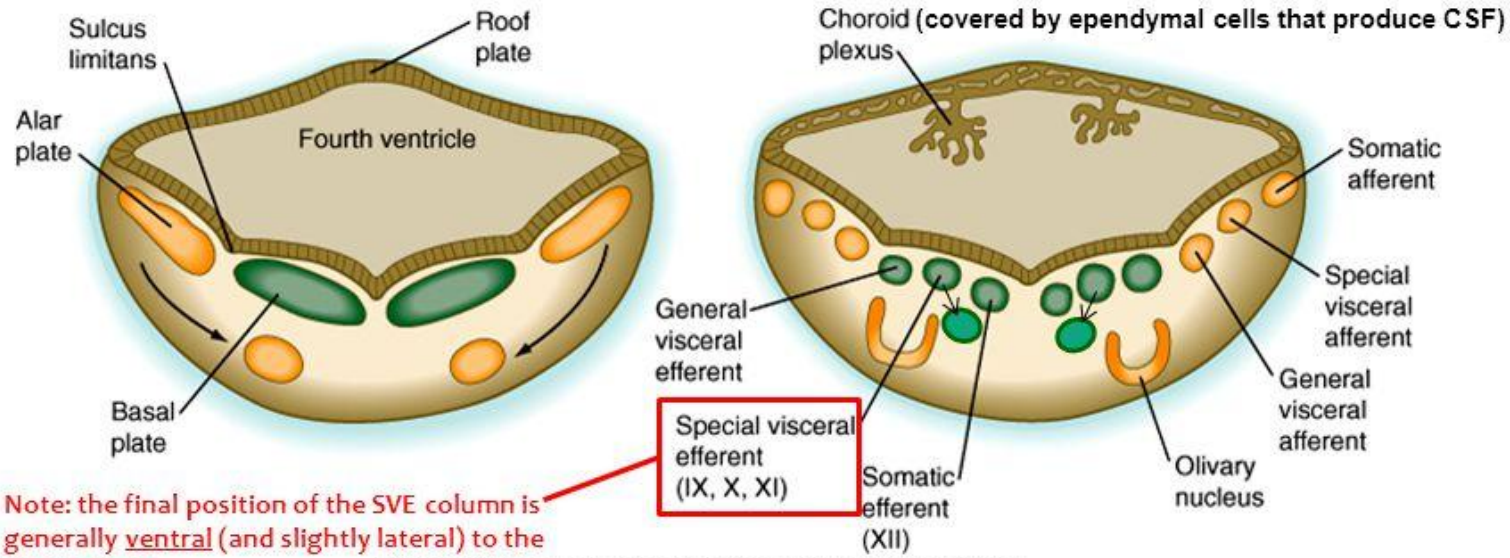

Note: the final position of the SVE column is generally ventral (and slightly lateral) to the GSE column

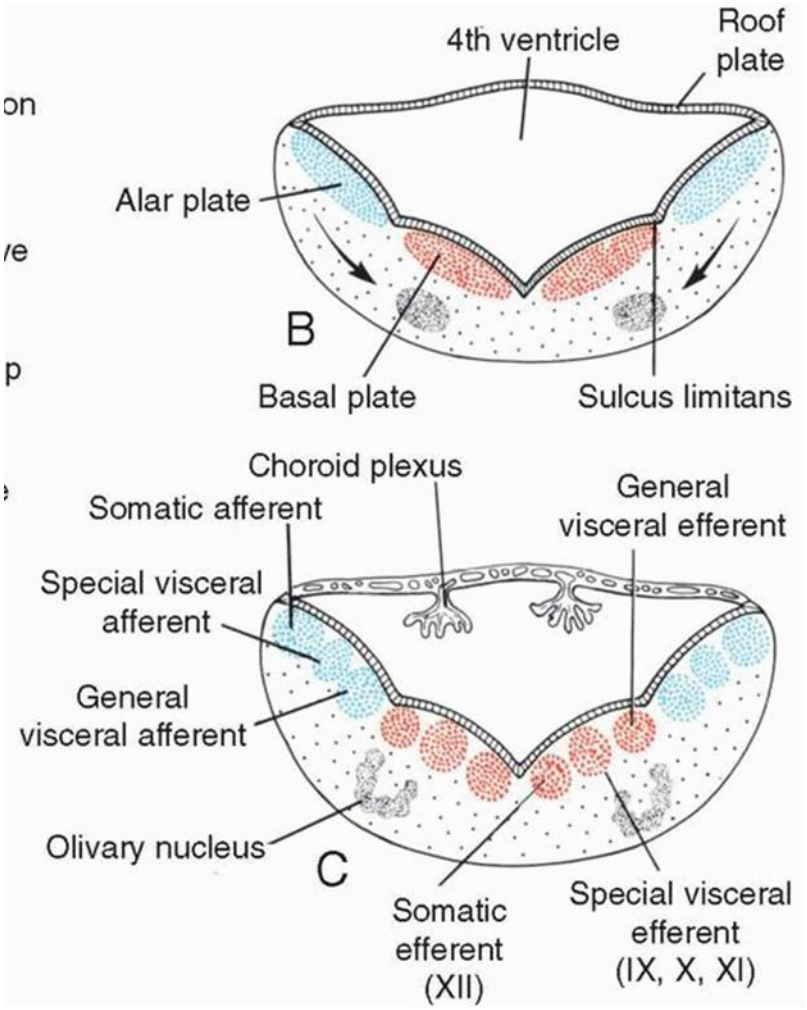
4th ventricle
Roof plate
Alar plate
B
Basal plate
Sulcus limitans
Choroid plexus
Somatic afferent
General visceral efferent
Special visceral afferent
General visceral afferent
Olivary nucleus
C
Somatic efferent (XII)
Special visceral efferent (IX, X, XI)

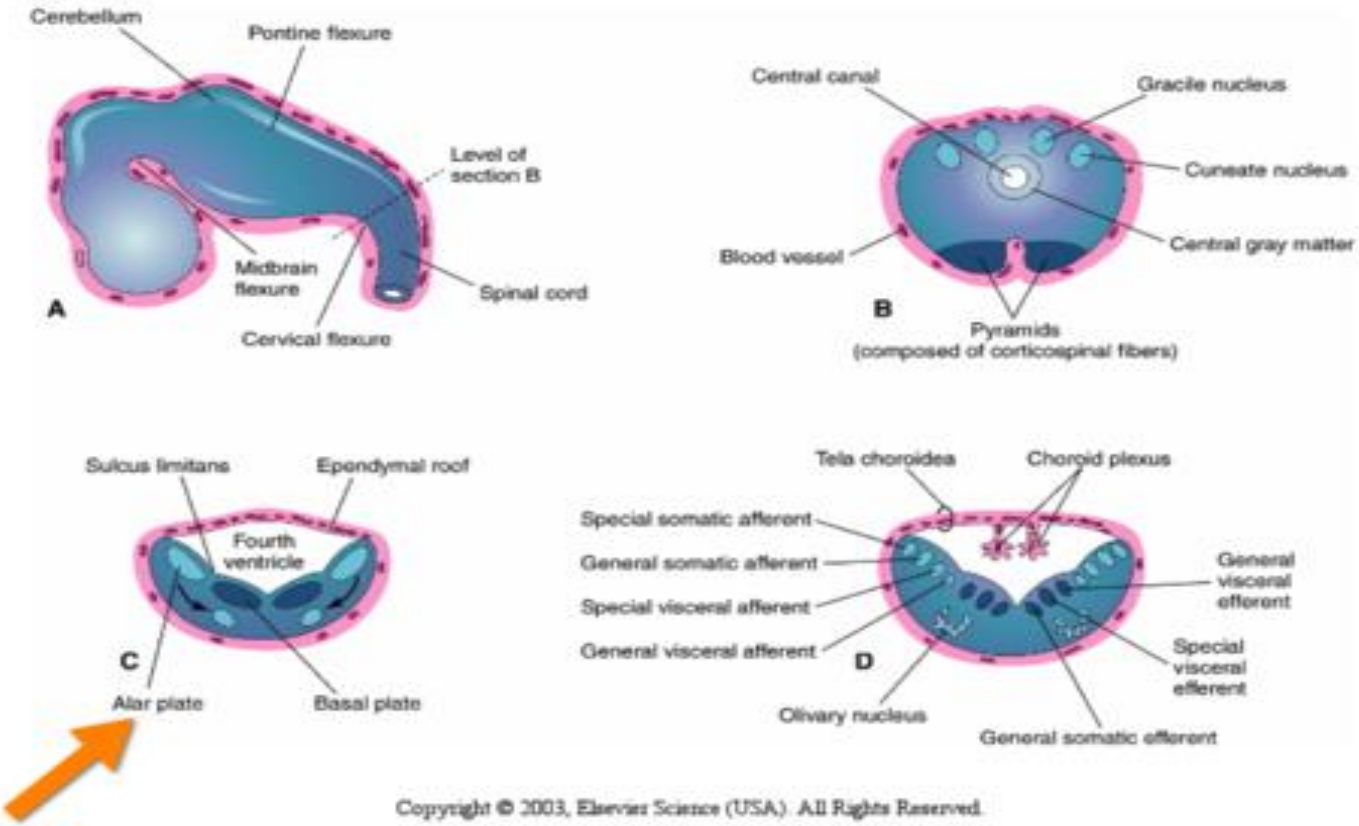

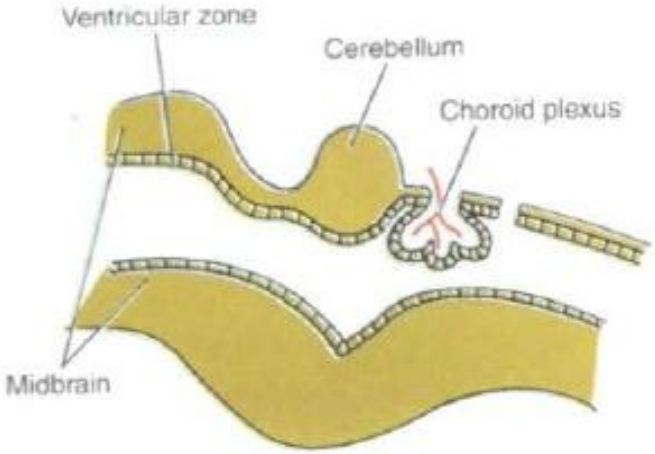
Ventricular zone
Cerebellum
Choroid plexus
Midbrain

1

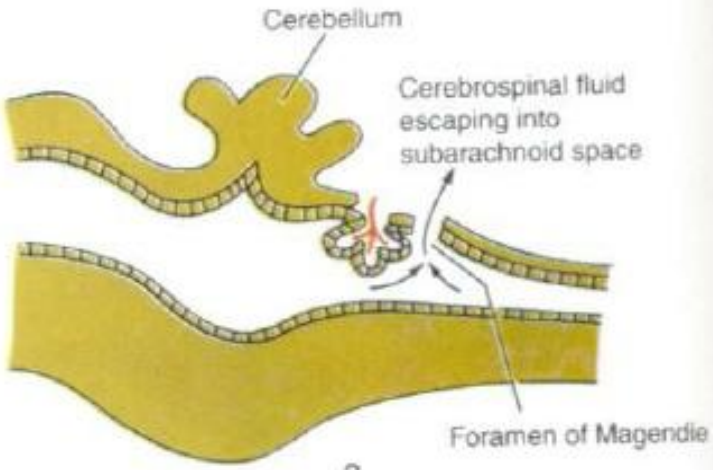
Cerebellum
Cerebrospinal fluid escaping into subarachnoid space
Foramen of Magendie

2

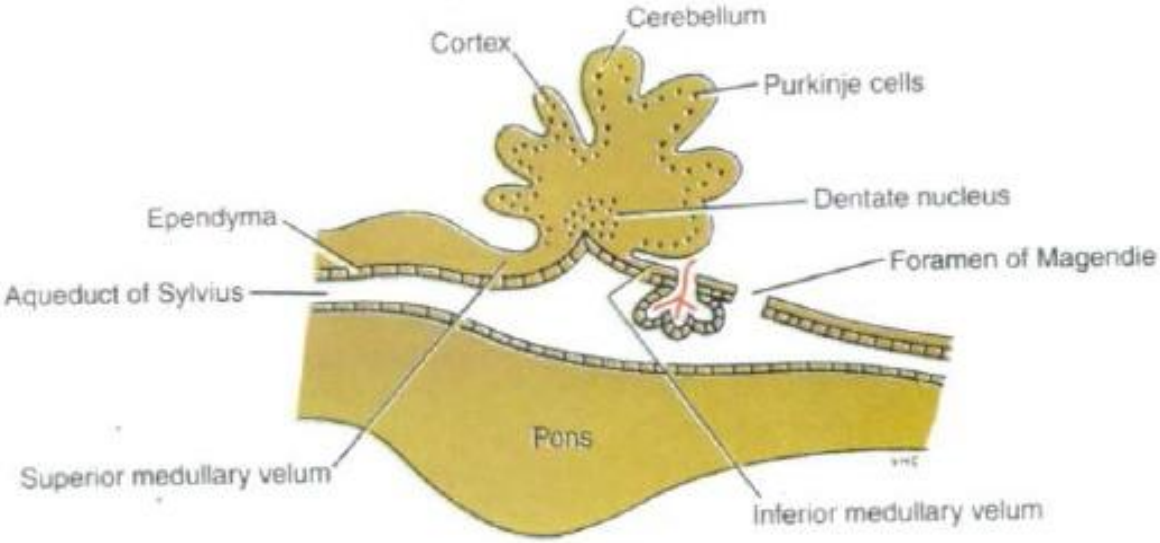
Cerebellum
Cortex
Purkinje cells
Dentate nucleus
Ependyma
Foramen of Magendie
Aqueduct of Sylvius
Pons
Superior medullary velum
Inferior medullary velum

3

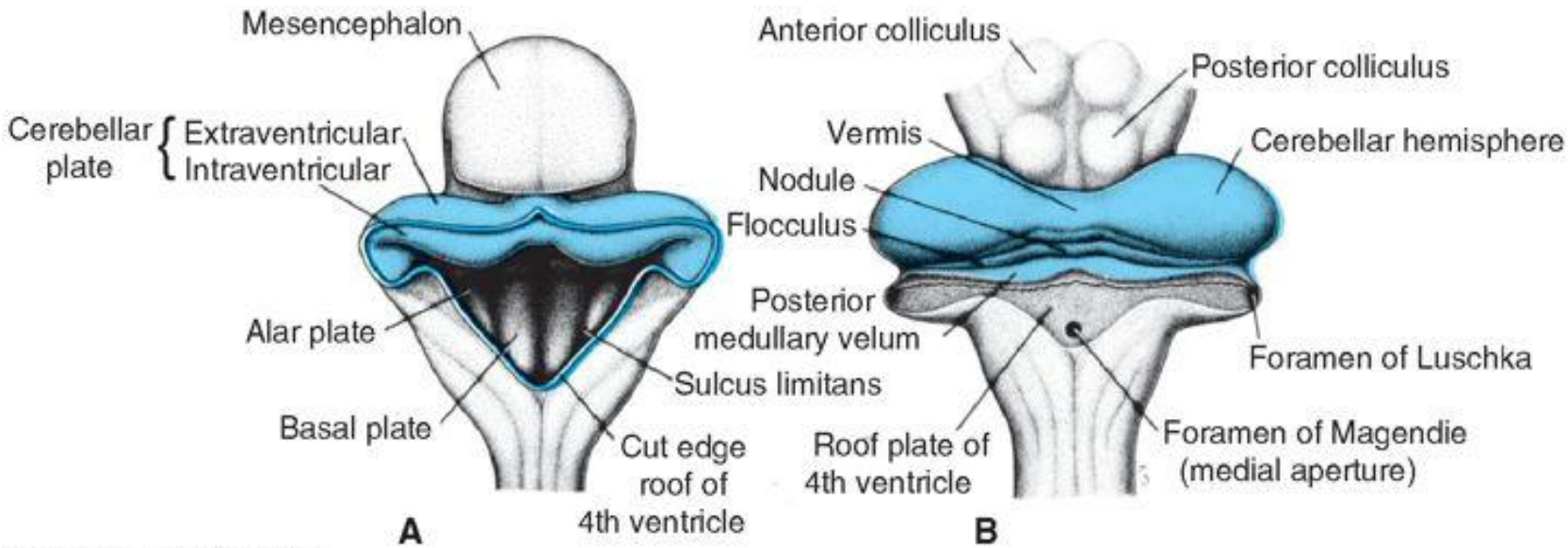

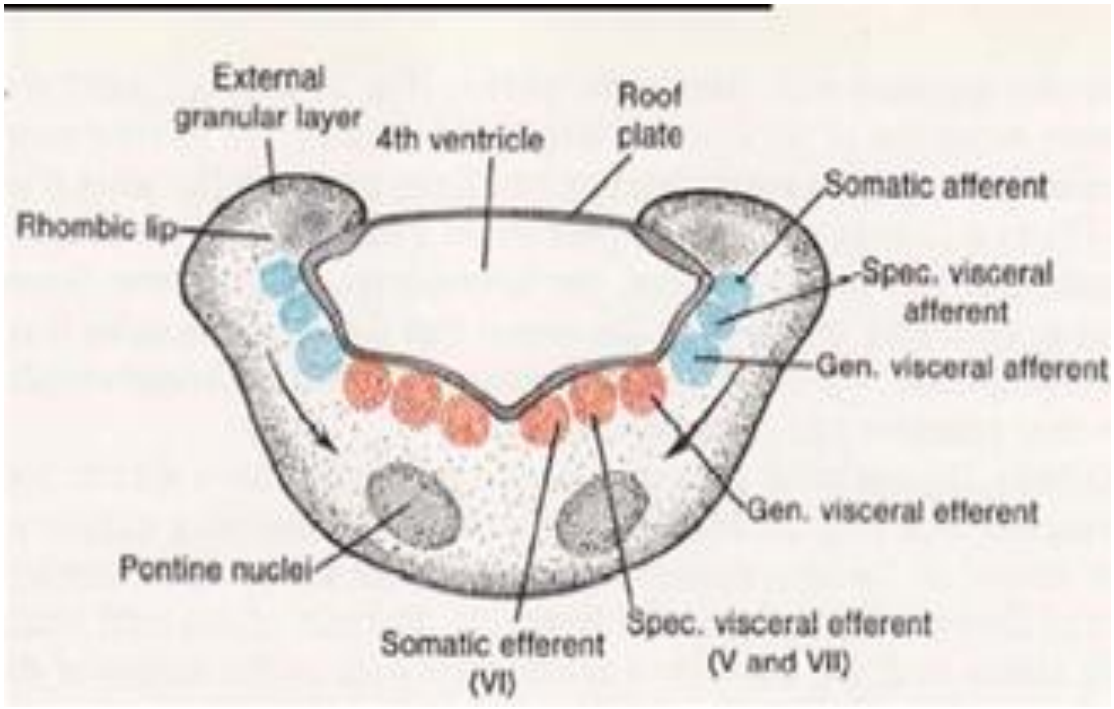
External
granular layer
4th ventricle
Roof
plate
Rhombic lip
Somatic afferent
Spec. visceral
afferent
Gen. visceral afferent
Gen. visceral efferent
Pontine nuclei
Somatic efferent
(VI)
Spec. visceral efferent
(V and VII)

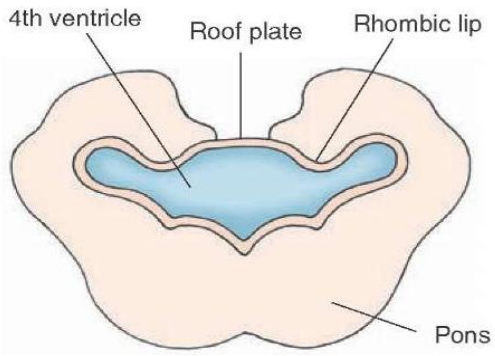
4th ventricle
Roof plate
Rhombic lip
Pons

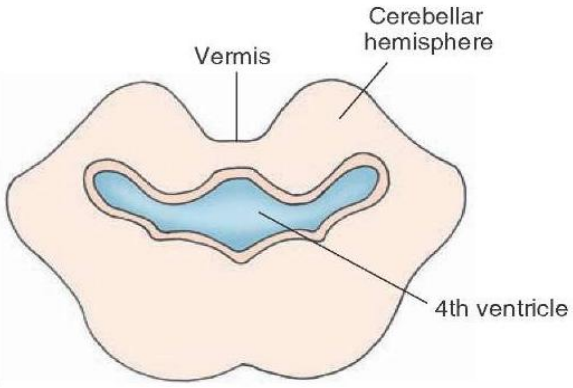
Cerebellar hemisphere
Vermis
4th ventricle

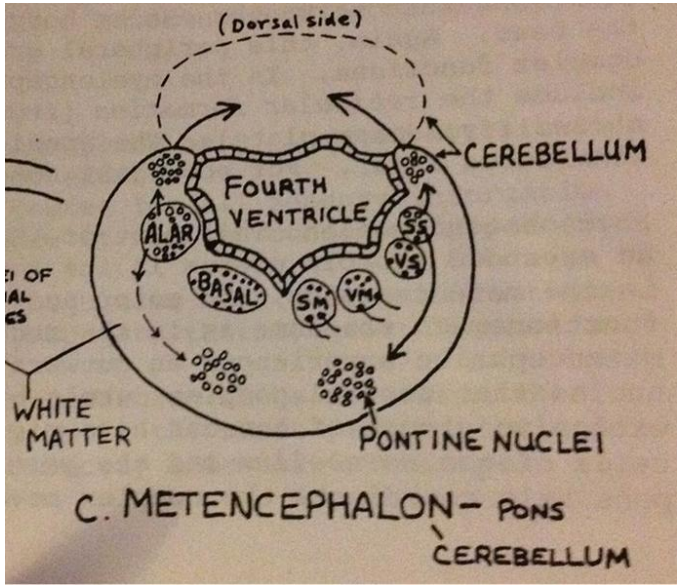
(Dorsal side)
CEREBELLUM
FOURTH VENTRICLE
ALAR
BASAL
SS
VS
SM
VM
WHITE MATTER
PONTINE NUCLEI
C. METENCEPHALON – PONS
CEREBELLUM

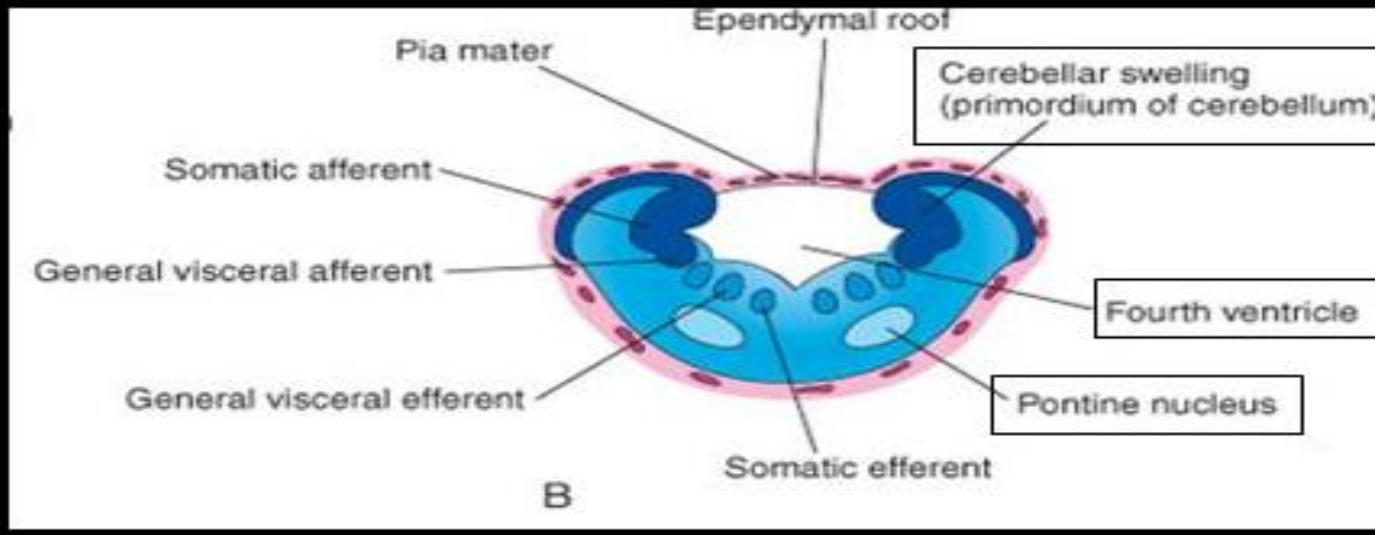
Ependymal roof
Pia mater
Cerebellar swelling
(primordium of cerebellum)
Somatic afferent
General visceral afferent
Fourth ventricle
General visceral efferent
Pontine nucleus
Somatic efferent
B

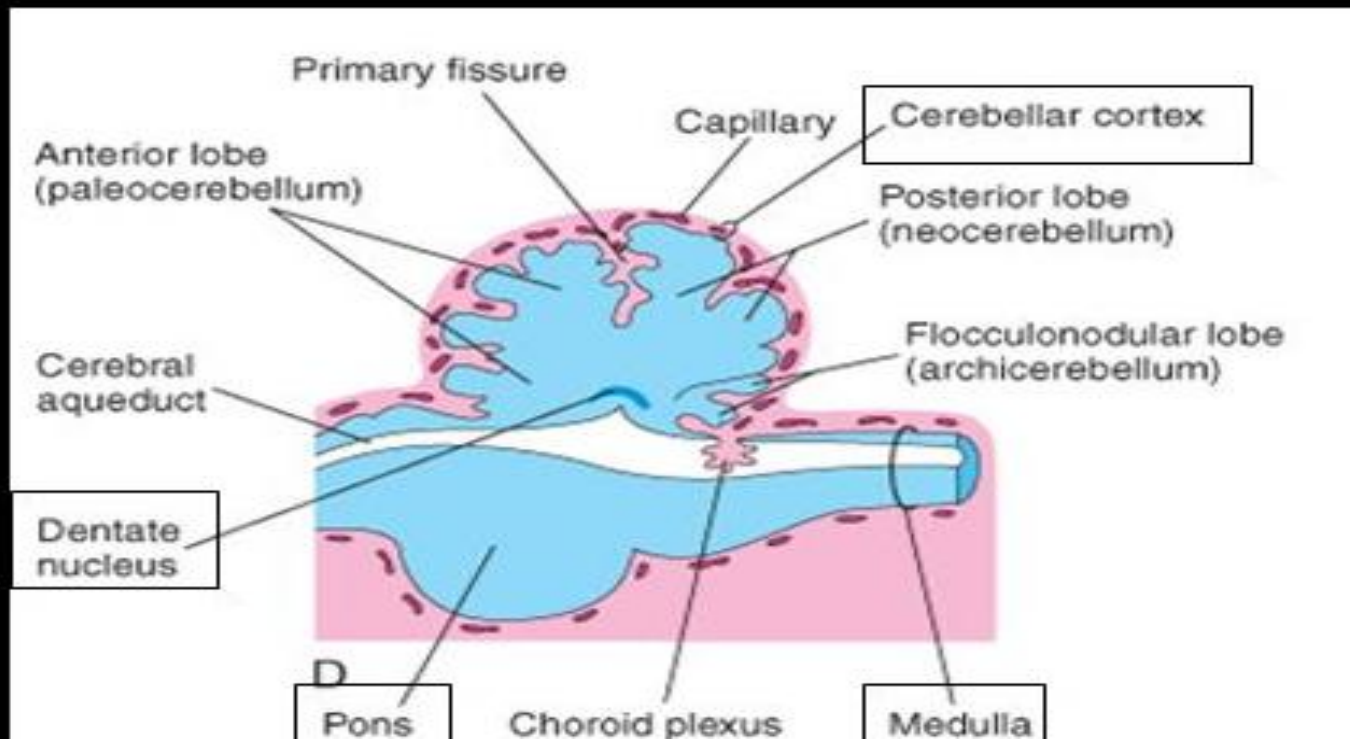
Primary fissure
Capillary
Cerebellar cortex
Anterior lobe
(paleocerebellum)
Posterior lobe
(neocerebellum)
Flocculonodular lobe
(archicerebellum)
Cerebral
aqueduct
Dentate
nucleus
D
Pons
Choroid plexus
Medulla

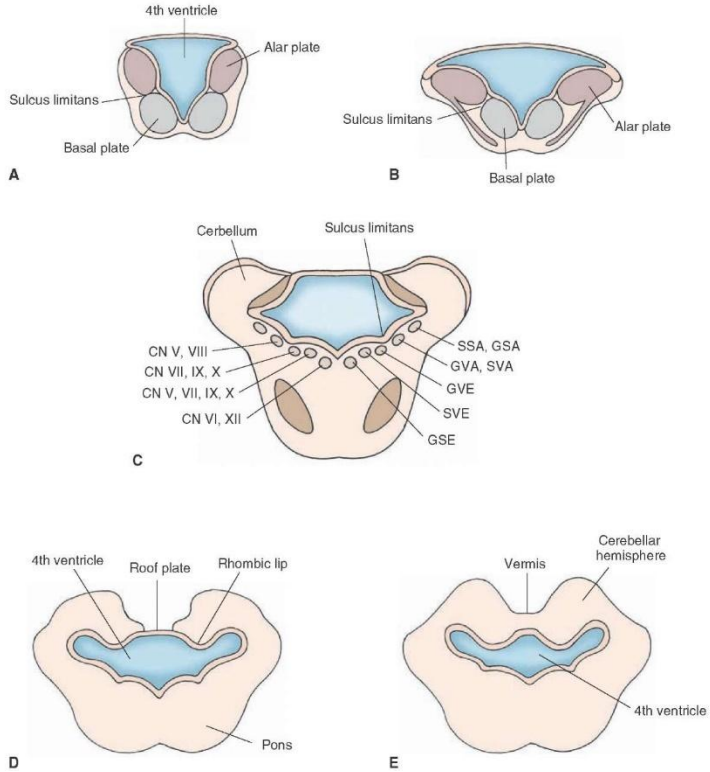

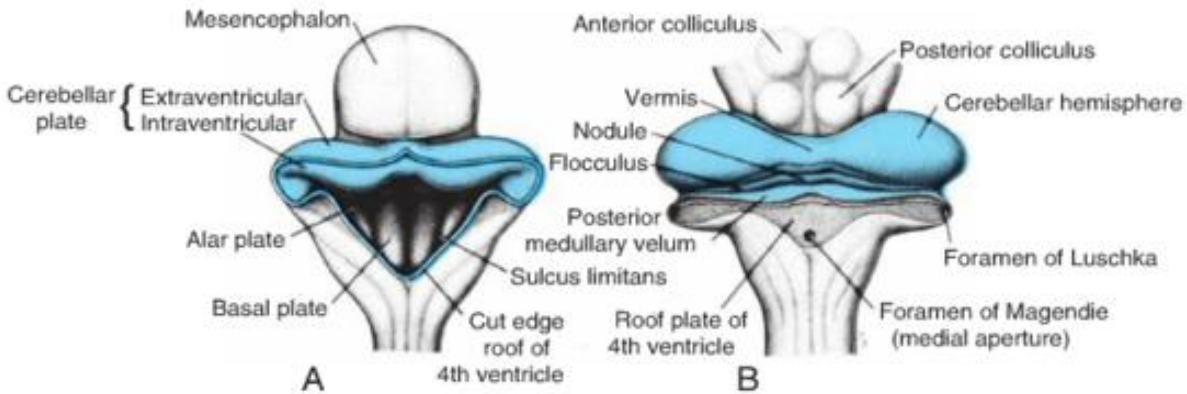

Figure 17.20 **A.** Dorsal view of the mesencephalon and rhombencephalon in an 8-week embryo. The roof of the fourth ventricle has been removed, allowing a view of its floor. **B.** Similar view in a 4-month embryo. Note the choroidal fissure and the lateral and medial apertures in the roof of the fourth ventricle.

Development of the pons and cerebellum

Development of the pons and cerebellum

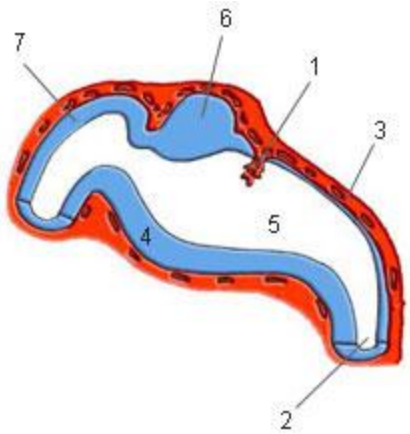

1. Choroid plexus
2. Medulla
3. Tela choroidea
4. Pons
5. 4th ventricle
6. Developing anterior lobe of cerebellum
7. Midbrain

Development of the pons and cerebellum

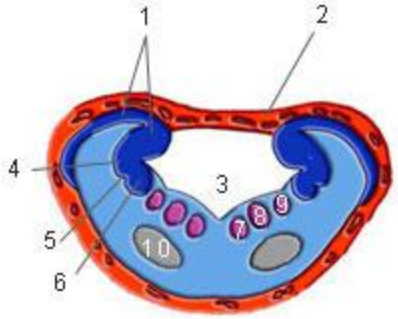

1. Developing cerebellum
2. Tela choroidea
3. 4th ventricle
4. Somatic afferent group
5. Special visceral afferent group
6. General visceral afferent group
7. Somatic efferent group
8. Special visceral efferent group
9. General visceral efferent group
10. Pontine nuclei

Compartmentalization of Cerebellar Neurogenesis

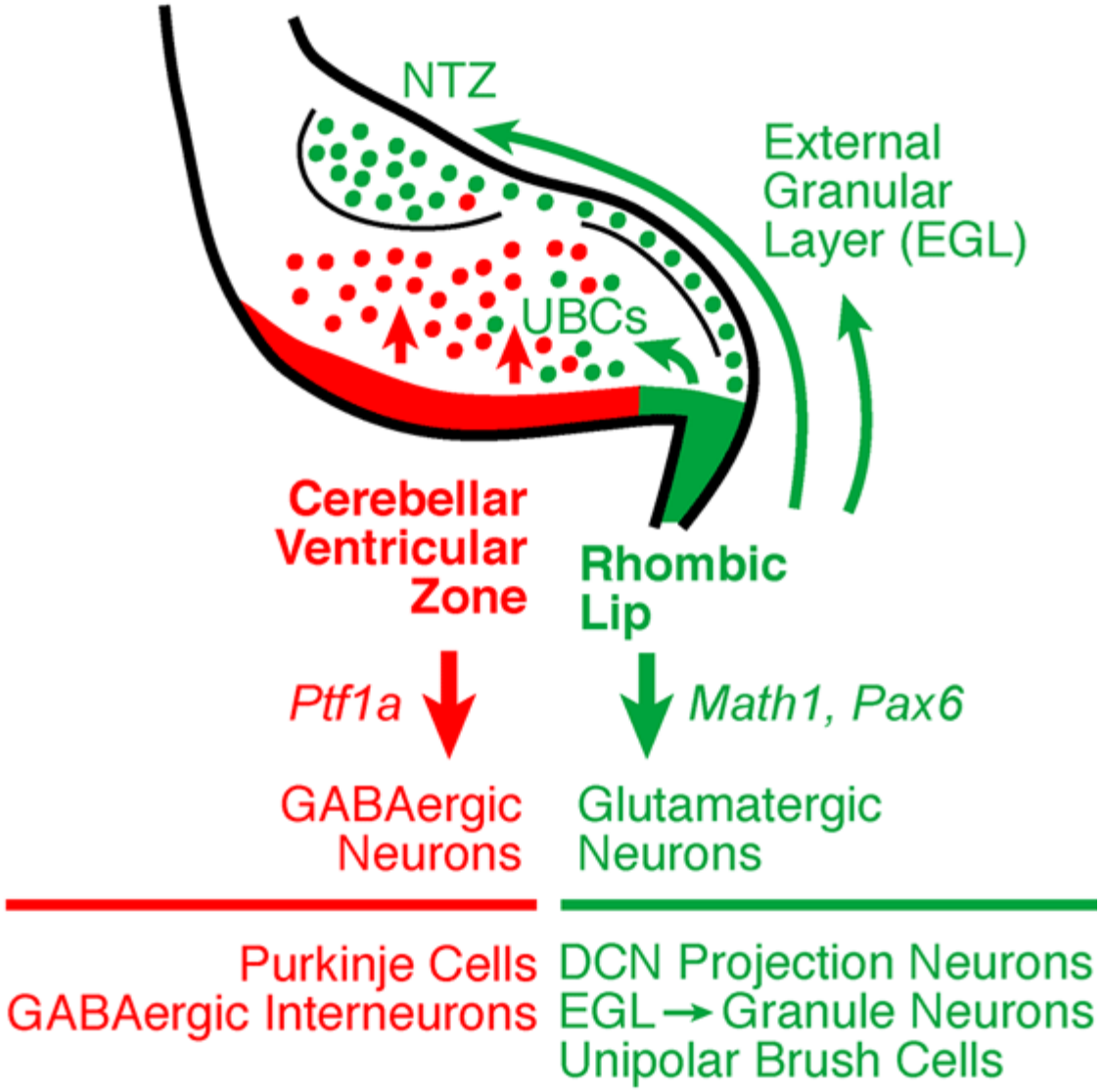

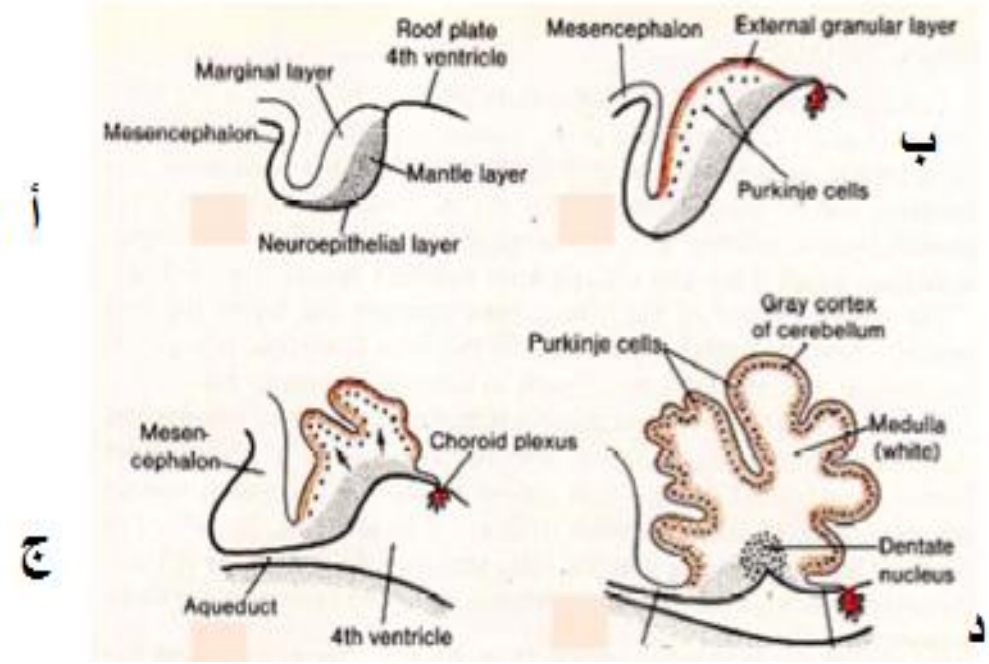

مقاطع سهمية عبر سطح الدماغ التالي يبين نمو المخيخ . أ- 8 أسابيع ، ب- 12 أسبوع ، ج- 13 اسبوع ، د- 15 أسبوع

لاحظ تشكل الطبقة الحبيبية الظاهرة على سطح الصفيحة المخيخية (ب و ج) . خلال المراحل المتأخرة تهاجر خلايا الطبقة الحبيبية الظاهرة نحو سطح الصفيحة المخيخية لتختلط مع خلايا بوركنج وتشكل القشرة النهائية للمخيخ .

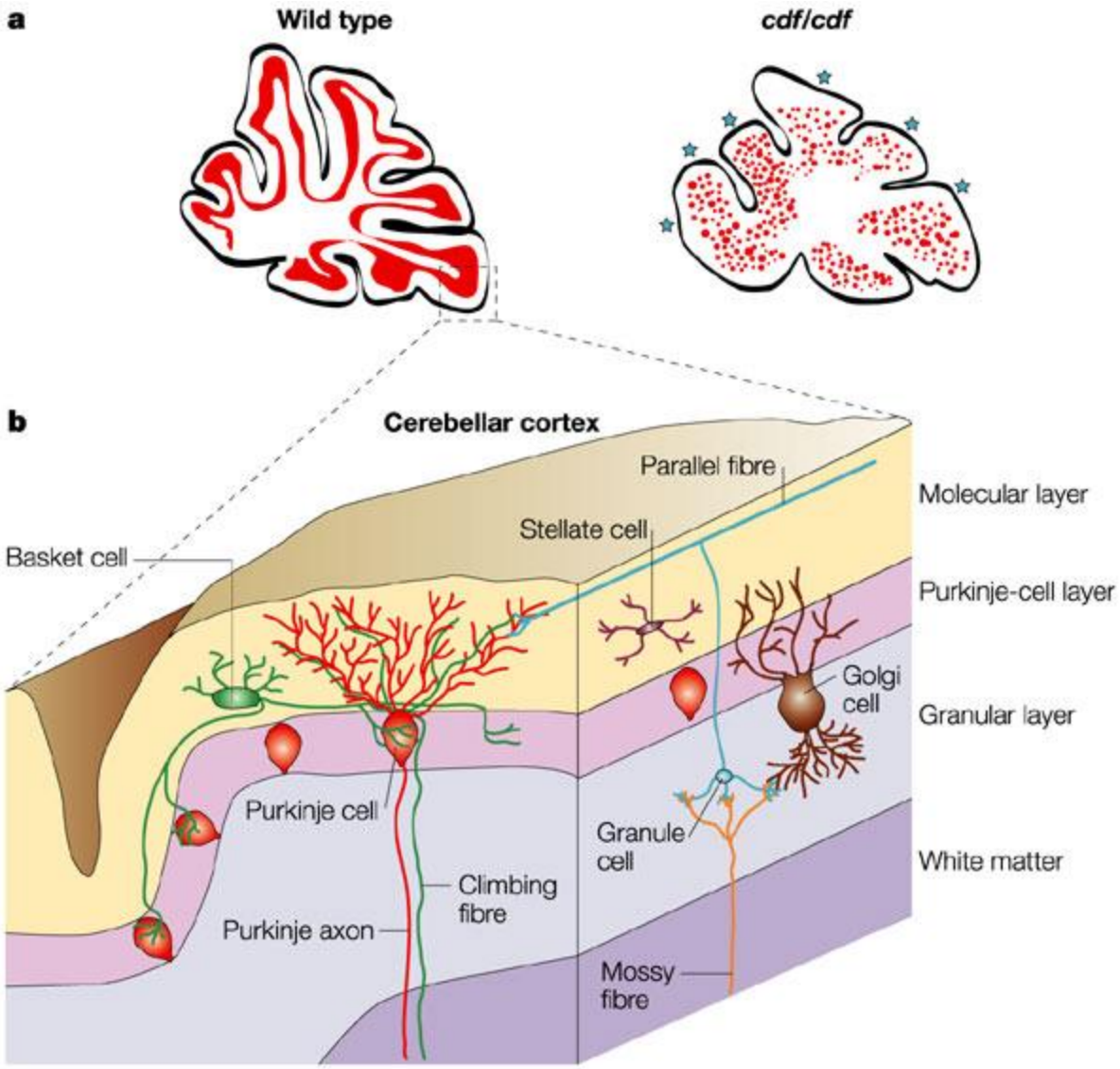

Nature Reviews | Molecular Cell Biology

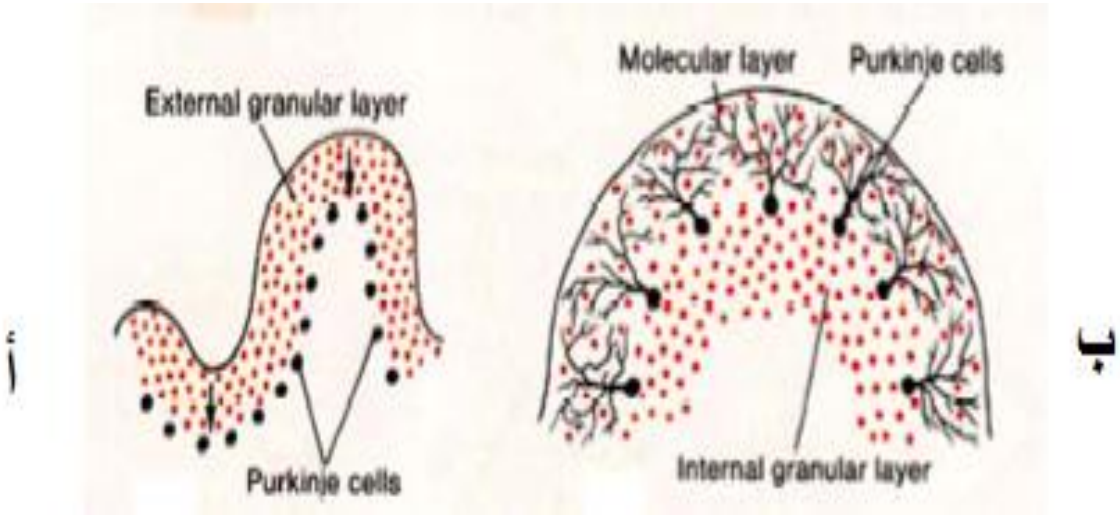

مراحل نمو القشرة المخيخية . أ – تشكل الطبقة الحبيبية الظاهرة على سطح المخيخ طبقة تكاثرية تنشأ منها الخلايا الحبيبية ، وهي تهاجر نحو الداخل من السطح (الأسهم) . ب – القشرة المخيخية بعد الولادة تبين خلايا بوركنج المتمايزة والطبقة الجزيئية على السطح والطبقة الحبيبية الباطنة تحت خلايا بوركنج .

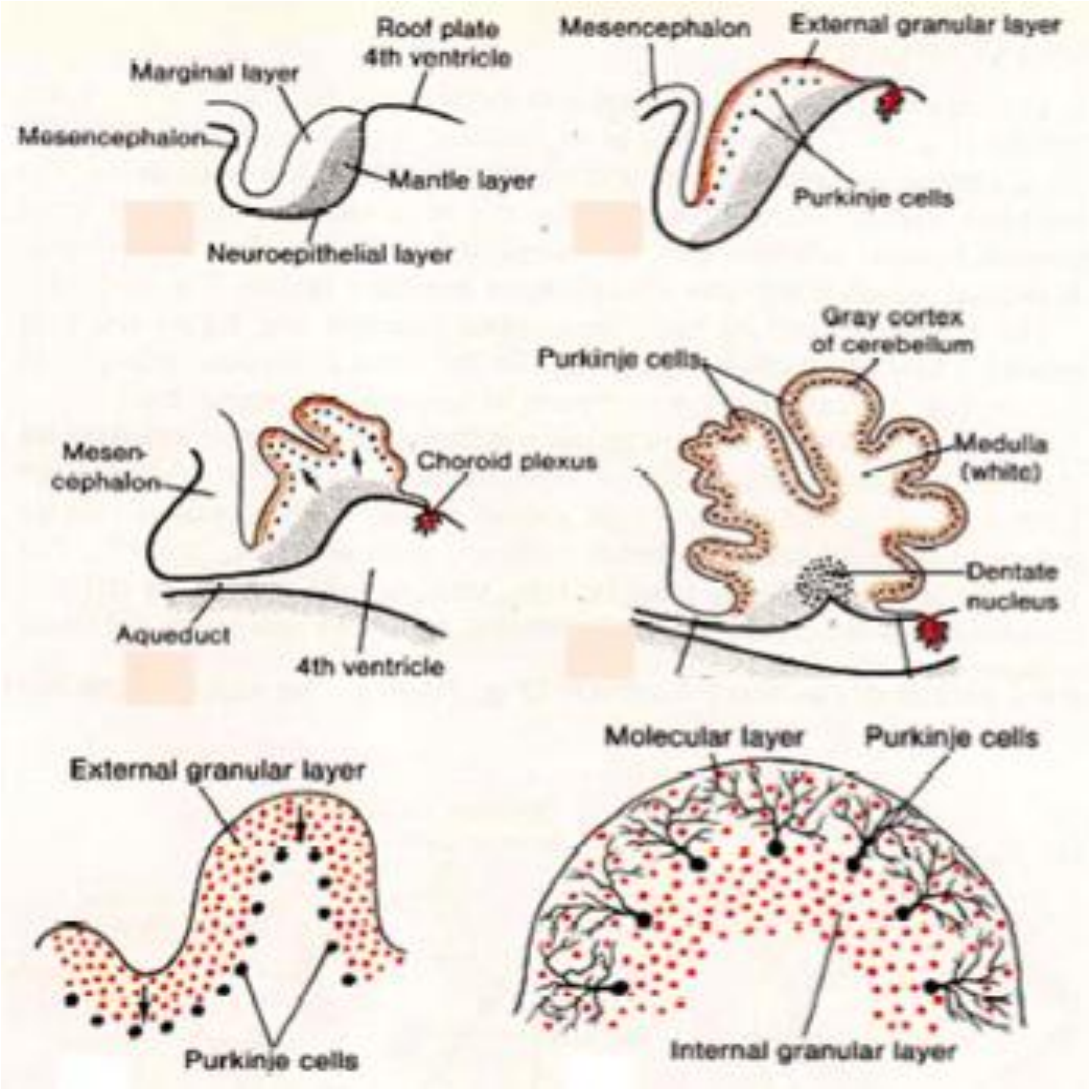
Roof plate
4th ventricle
Marginal layer
Mesencephalon
Mantle layer
Neuroepithelial layer
Mesencephalon
External granular layer
Purkinje cells
Gray cortex
of cerebellum
Purkinje cells
Medulla
(white)
Mesen-
cephalon
Choroid plexus
Dentate
nucleus
Aqueduct
4th ventricle
External granular layer
Purkinje cells
Molecular layer
Purkinje cells
Internal granular layer

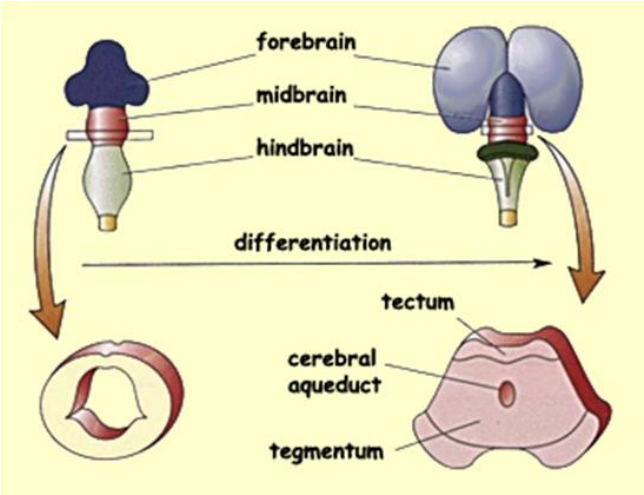
forebrain
midbrain
hindbrain
differentiation
tectum
cerebral aqueduct
tegmentum

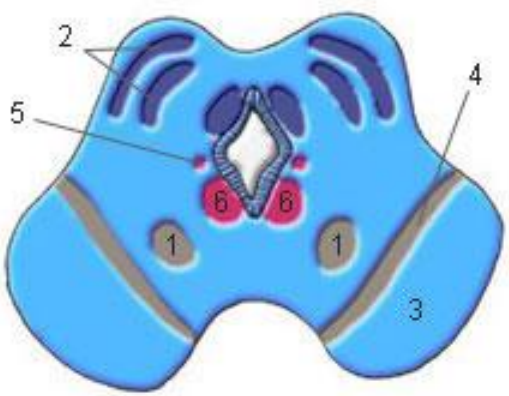
2
4
5
6
6
1
1
3

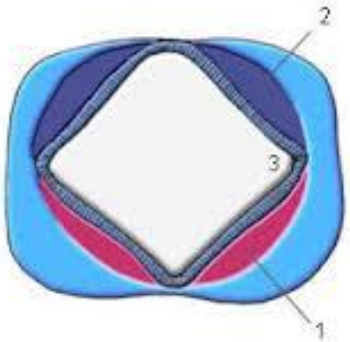
2
3
1

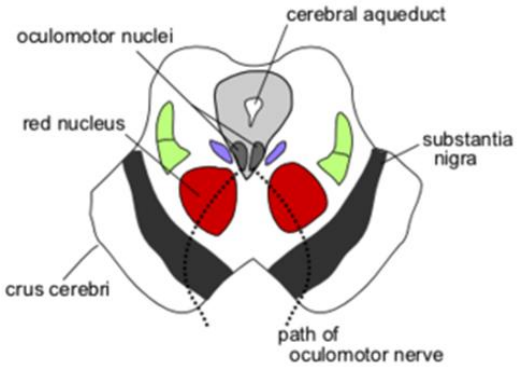
cerebral aqueduct
oculomotor nuclei
red nucleus
substantia nigra
crus cerebri
path of oculomotor nerve

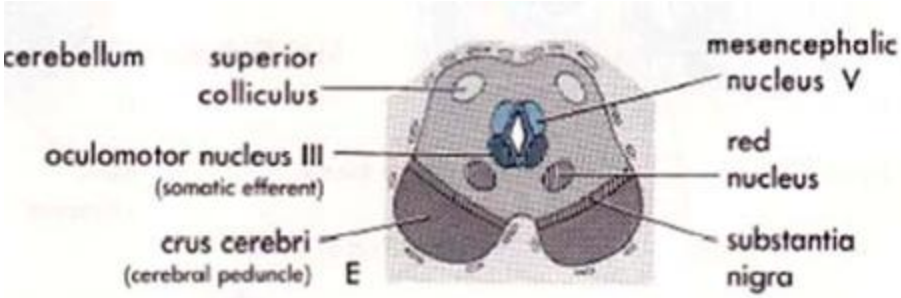
cerebellum
superior colliculus
oculomotor nucleus III
(somatic efferent)
crus cerebri
(cerebral peduncle)
E
mesencephalic nucleus V
red nucleus
substantia nigra

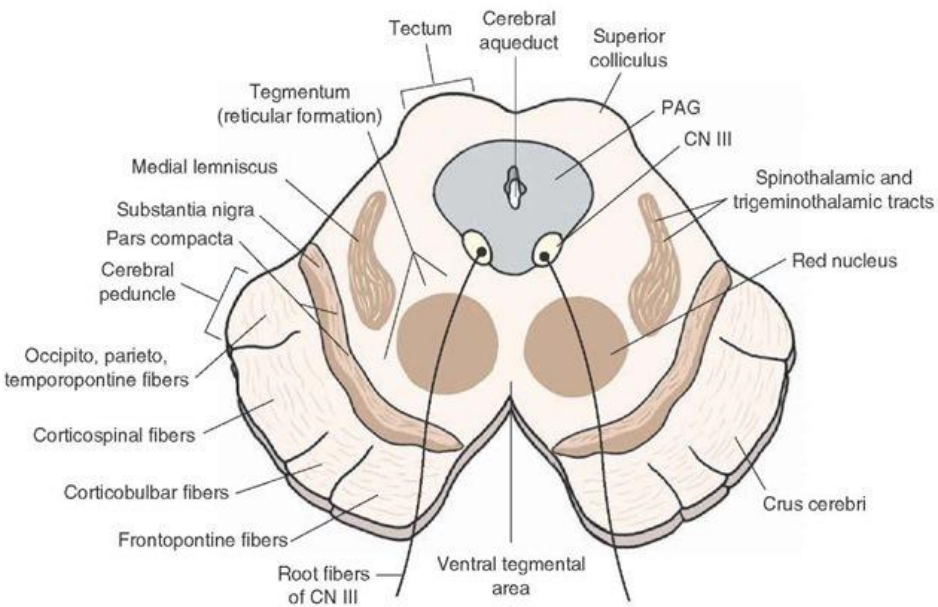
Tectum
Cerebral aqueduct
Superior colliculus
Tegmentum (reticular formation)
PAG
CN III
Medial lemniscus
Spinothalamic and trigeminothalamic tracts
Substantia nigra
Pars compacta
Red nucleus
Cerebral peduncle
Occipito, parieto, temporopontine fibers
Corticospinal fibers
Corticobulbar fibers
Crus cerebri
Frontopontine fibers
Root fibers of CN III
Ventral tegmental area

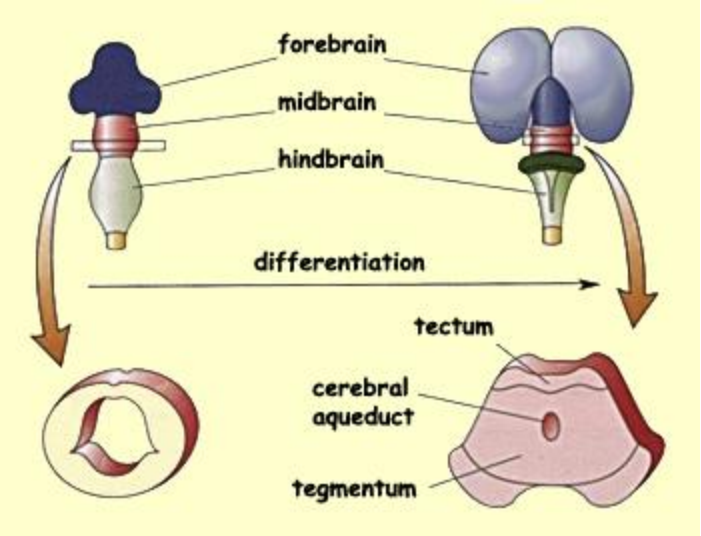
forebrain
midbrain
hindbrain
differentiation
tectum
cerebral aqueduct
tegmentum

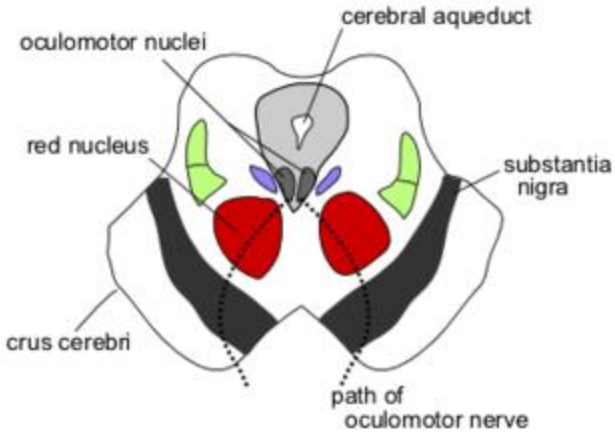
cerebral aqueduct
oculomotor nuclei
red nucleus
substantia nigra
crus cerebri
path of oculomotor nerve

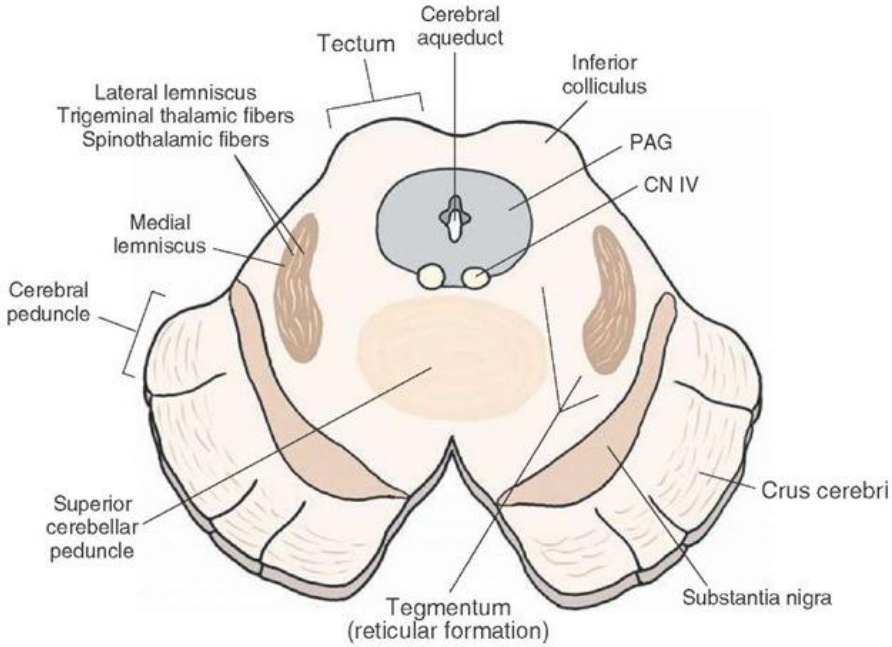
Cerebral aqueduct
Tectum
Inferior colliculus
Lateral lemniscus
Trigeminal thalamic fibers
Spinothalamic fibers
PAG
CN IV
Medial lemniscus
Cerebral peduncle
Crus cerebri
Superior cerebellar peduncle
Substantia nigra
Tegmentum (reticular formation)

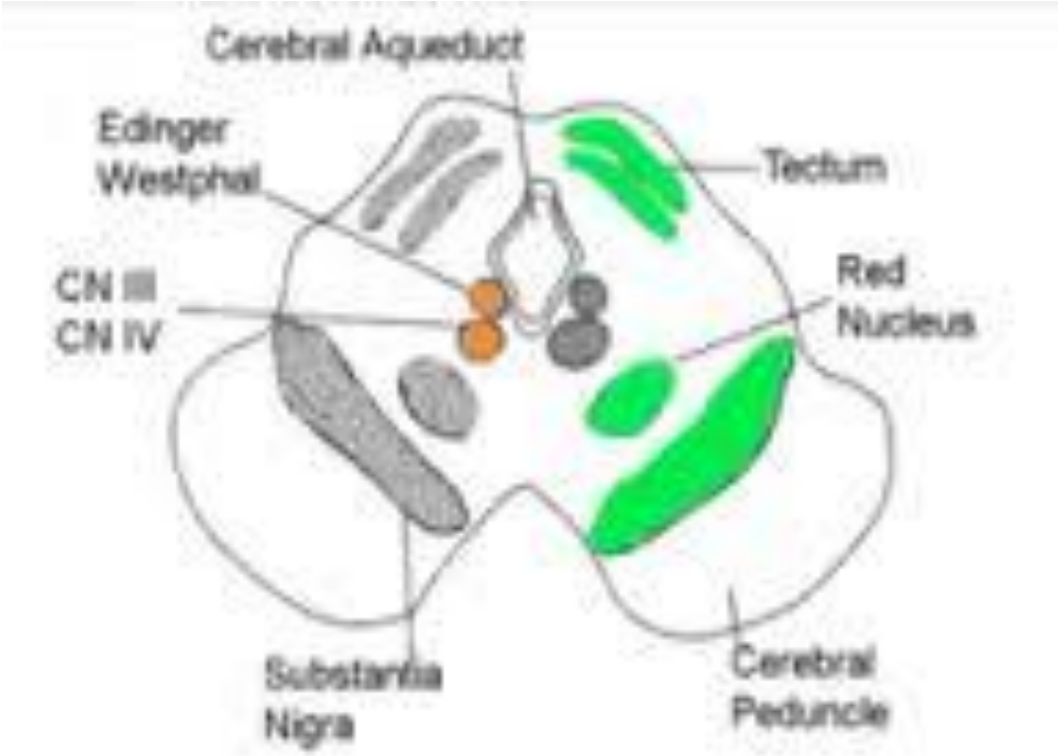
Cerebral Aqueduct
Edinger
Westphal
Tectum
CN III
CN IV
Red
Nucleus
Substantia
Nigra
Cerebral
Peduncle

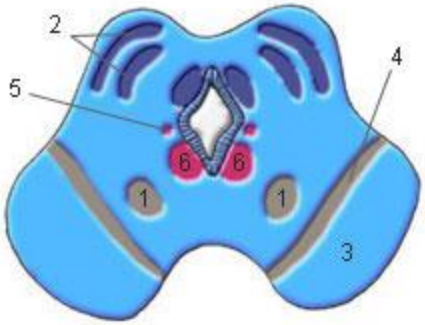
2
4
5
6
6
1
1
3

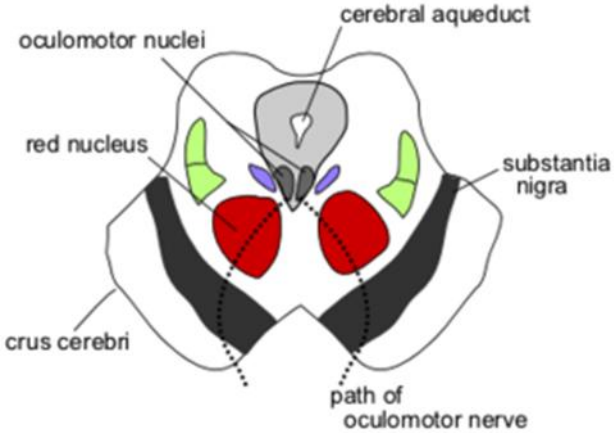
cerebral aqueduct
oculomotor nuclei
red nucleus
substantia nigra
crus cerebri
path of oculomotor nerve

تطور الدماغ البيني أو السريري

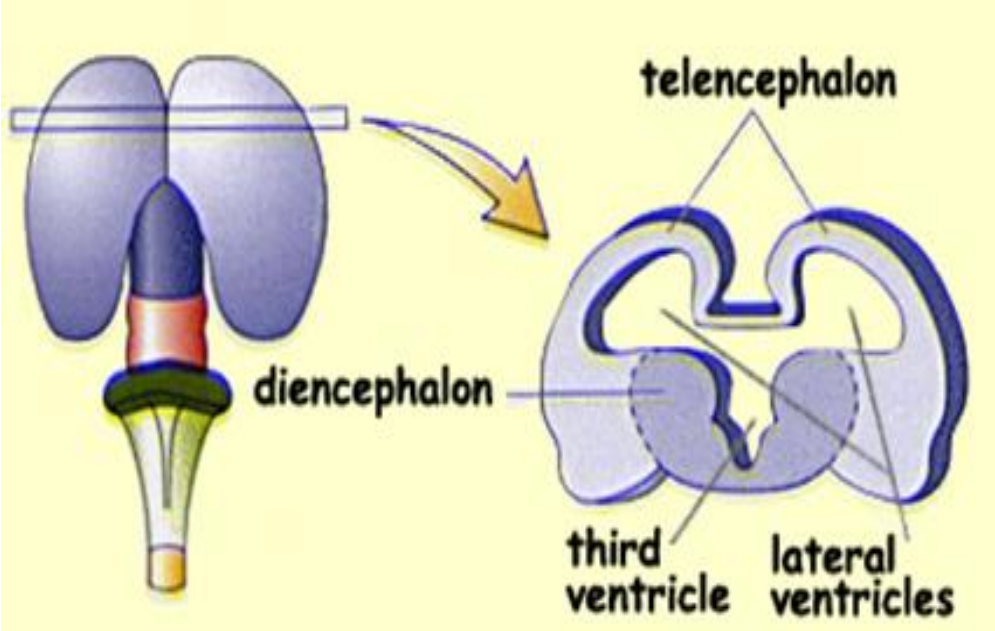

DIENCEPHALON

- Roof plate
- Alar plates = 2
- Absent floor & basal plates

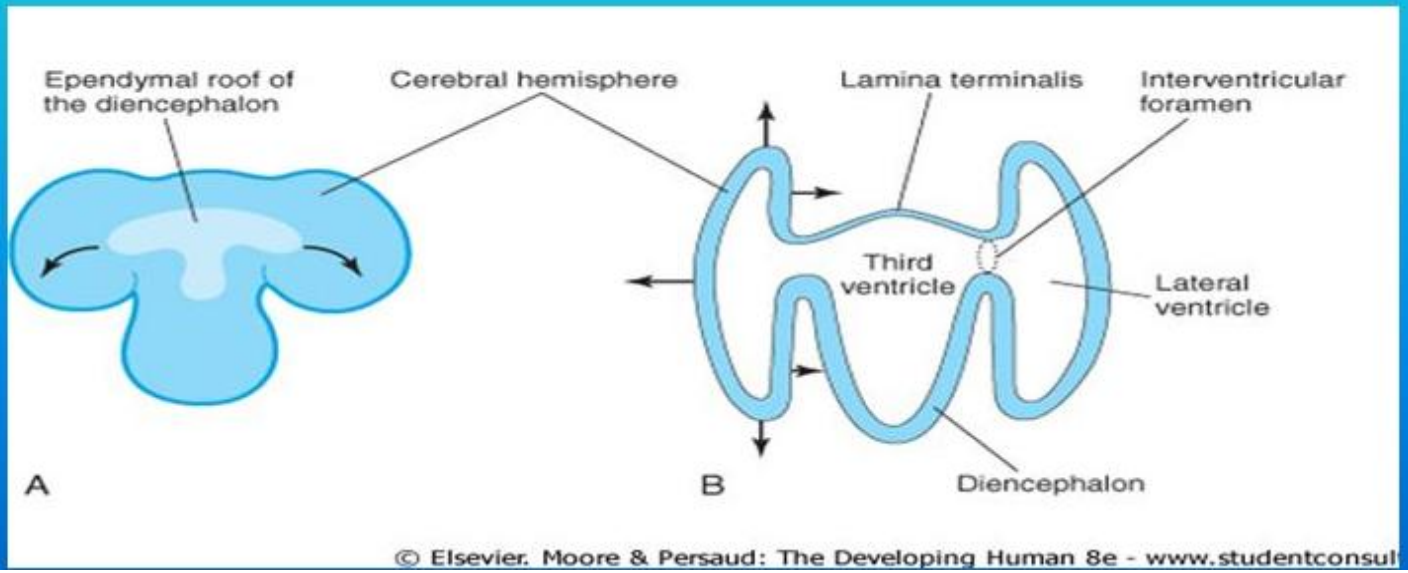

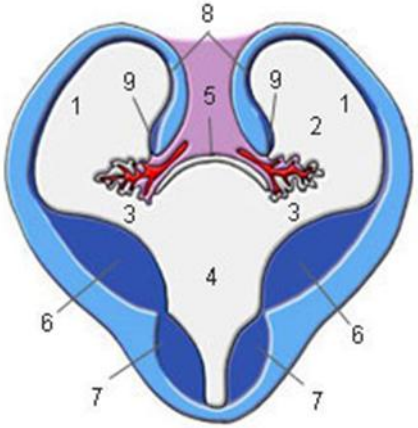

1. Lateral ventricle
2. Choroid plexus
3. Foramen of Monro
4. 3rd ventricle
5. Ependymal roof of the 3rd ventricle
6. Corpus striatum
7. Hypothalamus
8. Neopallium
9. Hippocampus

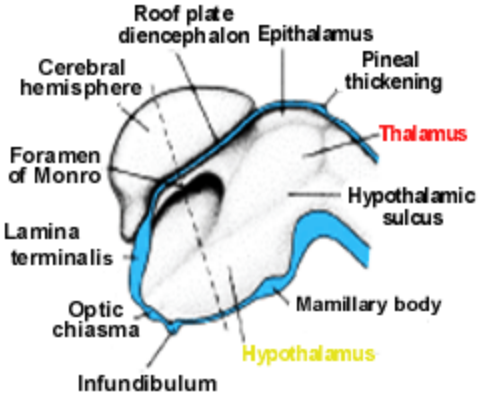

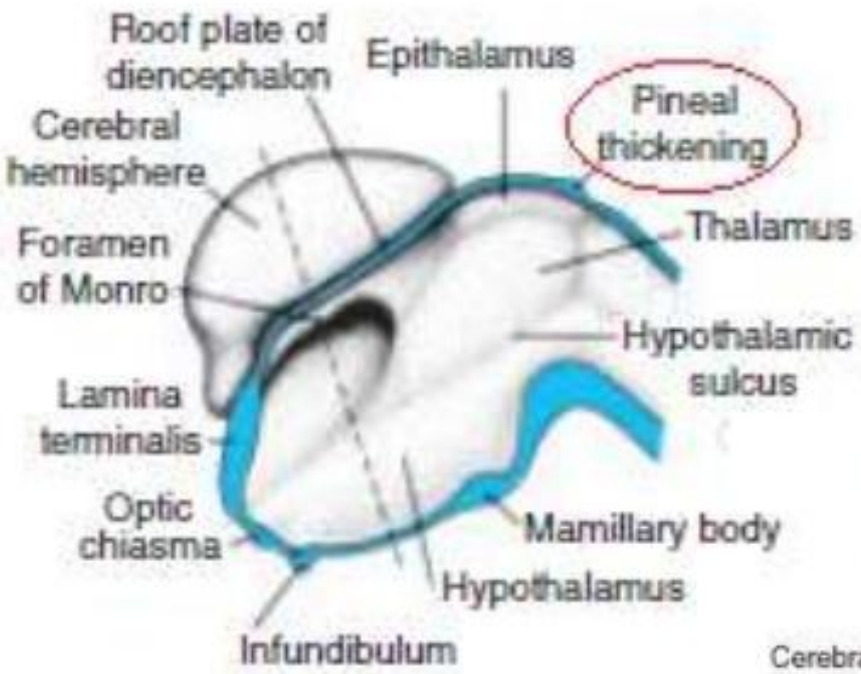
Roof plate of diencephalon
Epithalamus
Pineal thickening
Cerebral hemisphere
Thalamus
Foramen of Monro
Hypothalamic sulcus
Lamina terminalis
Optic chiasma
Mamillary body
Hypothalamus
Infundibulum

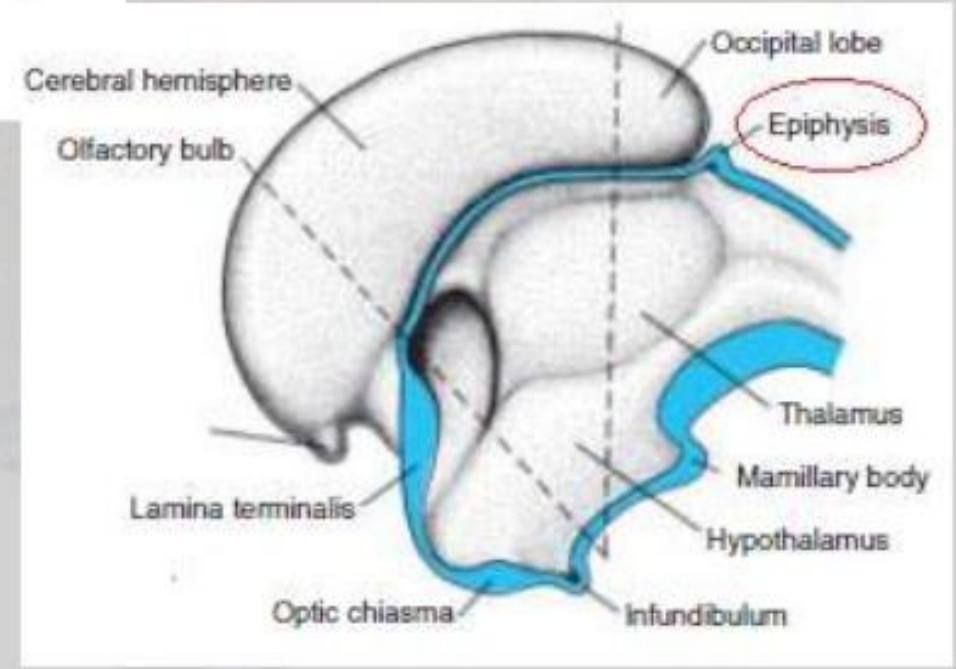
Occipital lobe
Cerebral hemisphere
Epiphysis
Olfactory bulb
Thalamus
Mamillary body
Lamina terminalis
Hypothalamus
Optic chiasma
Infundibulum

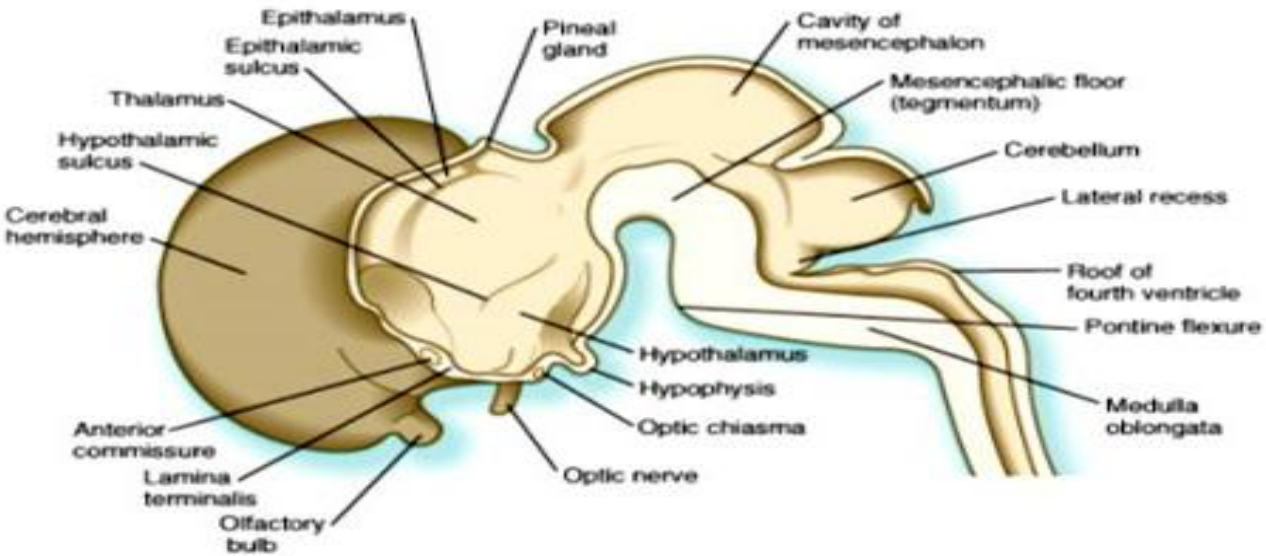

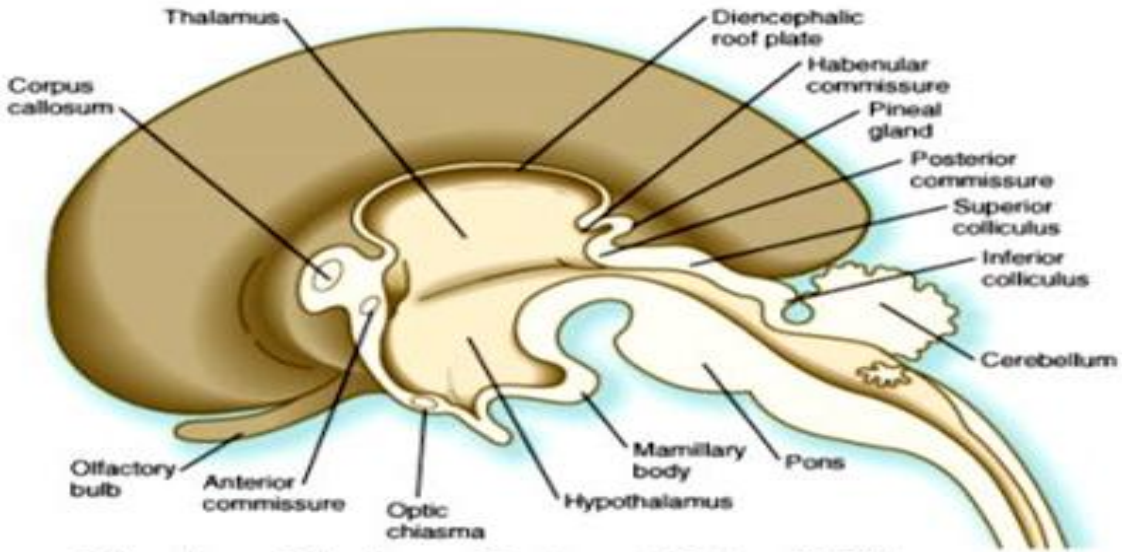

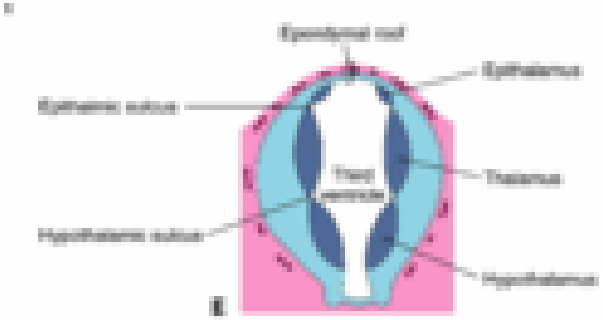
Ependymal roof
Epithalamus
Epithalamic sulcus
Thalamus
Third ventricle
Hypothalamic sulcus
Hypothalamus

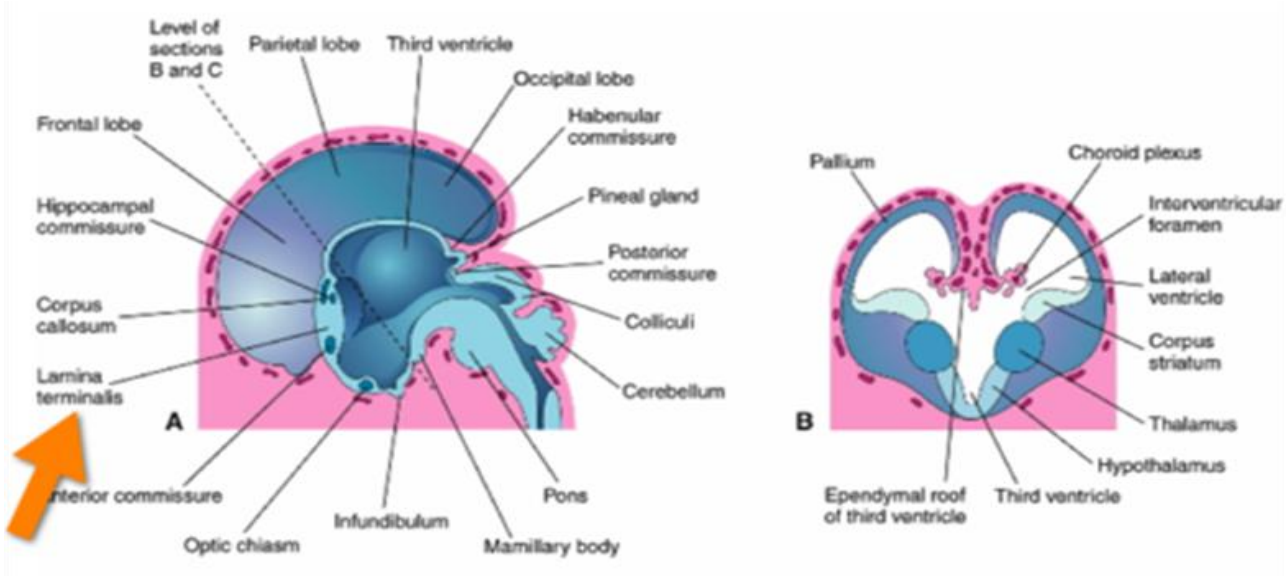
Level of sections B and C
Parietal lobe
Third ventricle
Occipital lobe
Frontal lobe
Habenular commissure
Pineal gland
Hippocampal commissure
Posterior commissure
Corpus callosum
Colliculi
Lamina terminalis
Cerebellum
A
Anterior commissure
Pons
Infundibulum
Optic chiasm
Mamillary body
Pallium
Choroid plexus
Interventricular foramen
Lateral ventricle
Corpus striatum
B
Thalamus
Hypothalamus
Ependymal roof of third ventricle
Third ventricle

في نهاية الأسبوع الخامس

في الأسبوع الـ

في الأسبوع الثامن

ماغ البيني

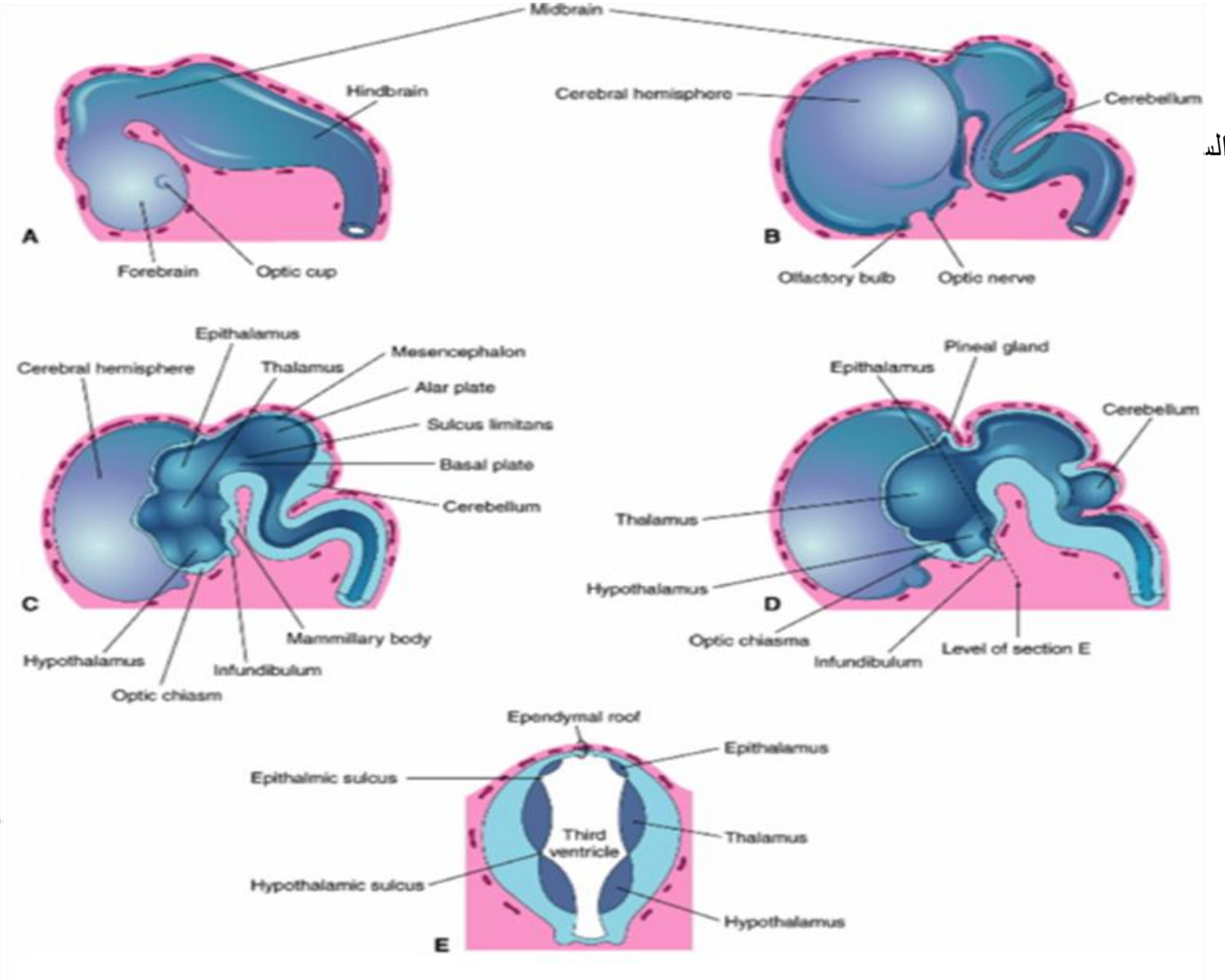

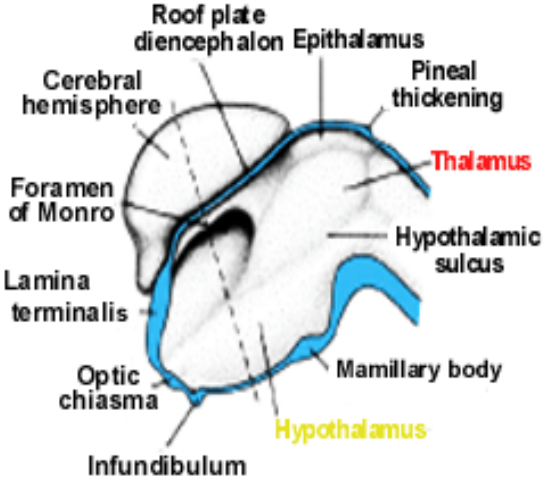

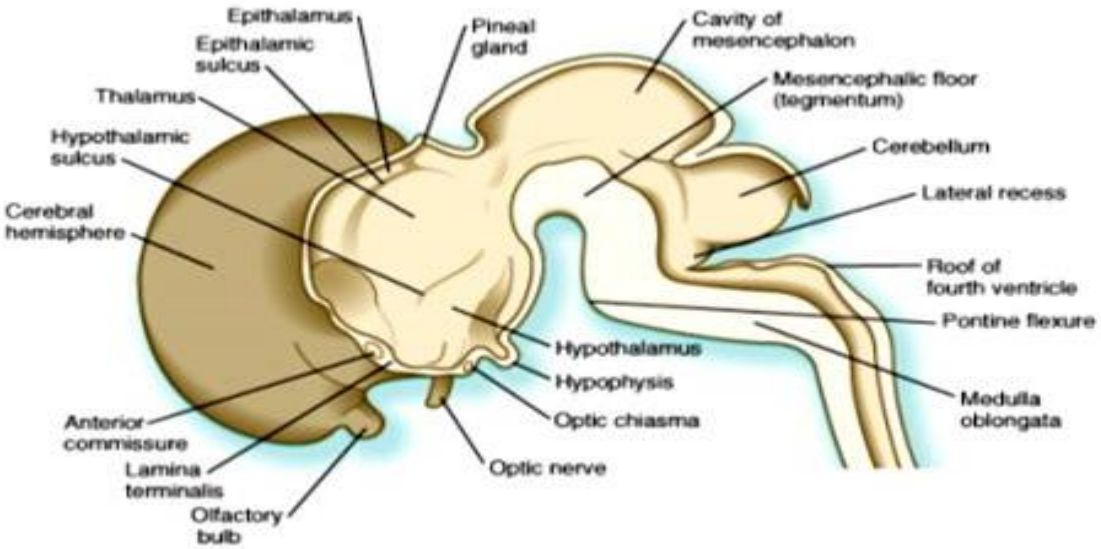

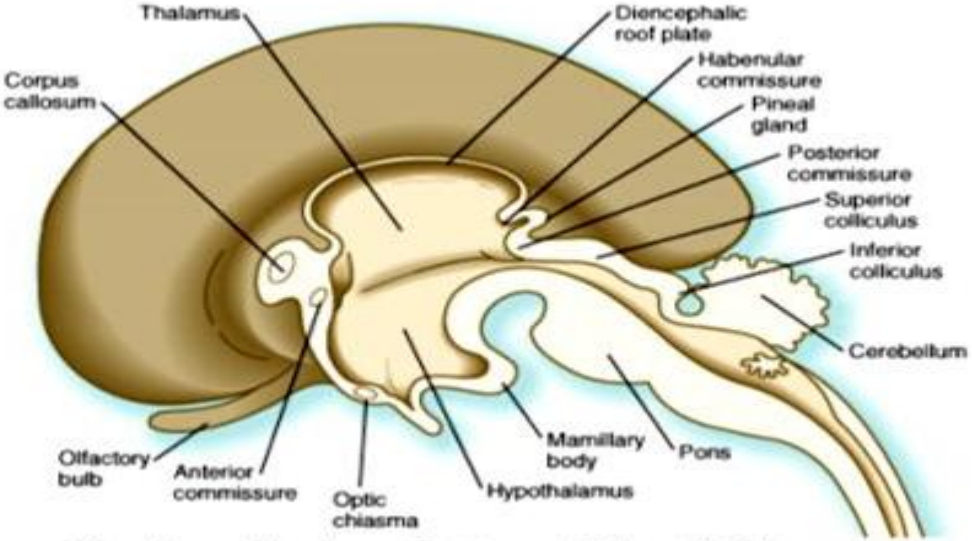

Diencephalon and telencephalon

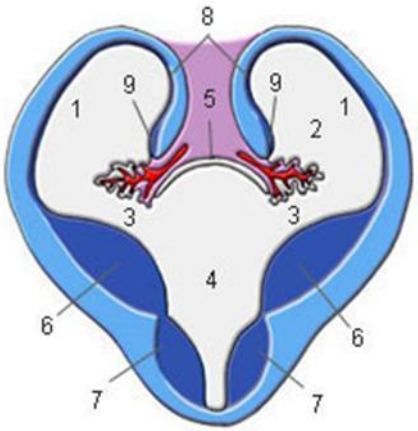

1. Lateral ventricle
2. Choroid plexus
3. Foramen of Monro
4. 3rd ventricle
5. Ependymal roof of the 3rd ventricle
6. Corpus striatum
7. Hypothalamus
8. Neopallium
9. Hippocampus

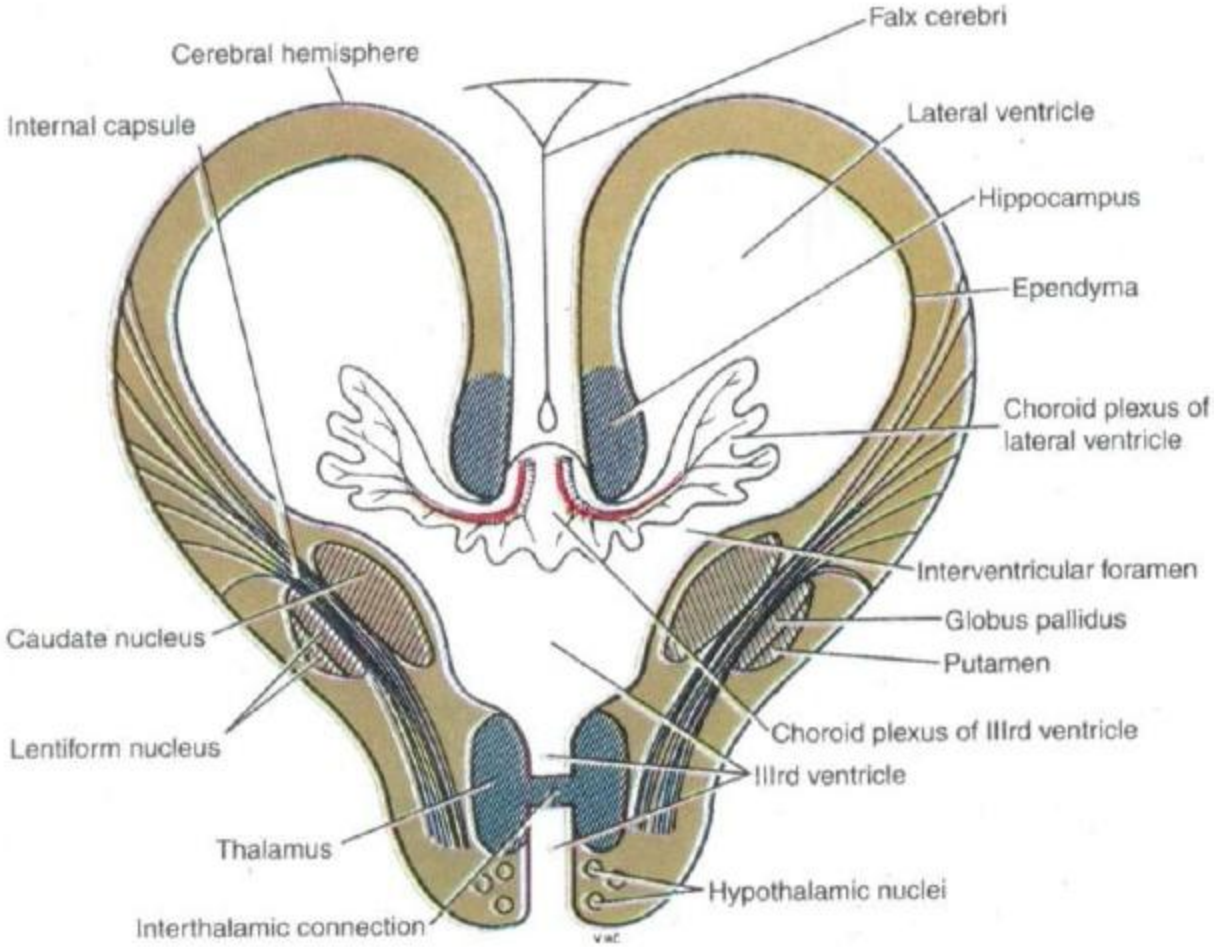
Falx cerebri
Cerebral hemisphere
Internal capsule
Lateral ventricle
Hippocampus
Ependyma
Choroid plexus of lateral ventricle
Interventricular foramen
Globus pallidus
Putamen
Caudate nucleus
Lentiform nucleus
Choroid plexus of IIIrd ventricle
IIIrd ventricle
Thalamus
Hypothalamic nuclei
Interthalamic connection

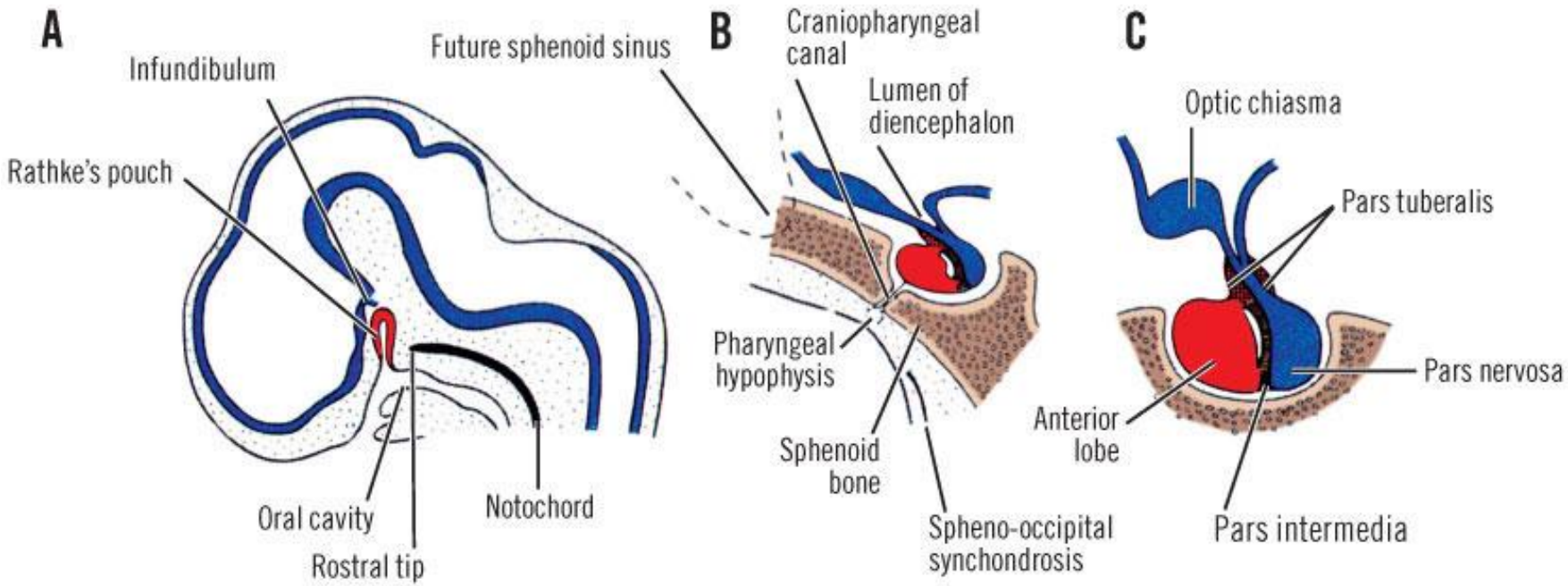

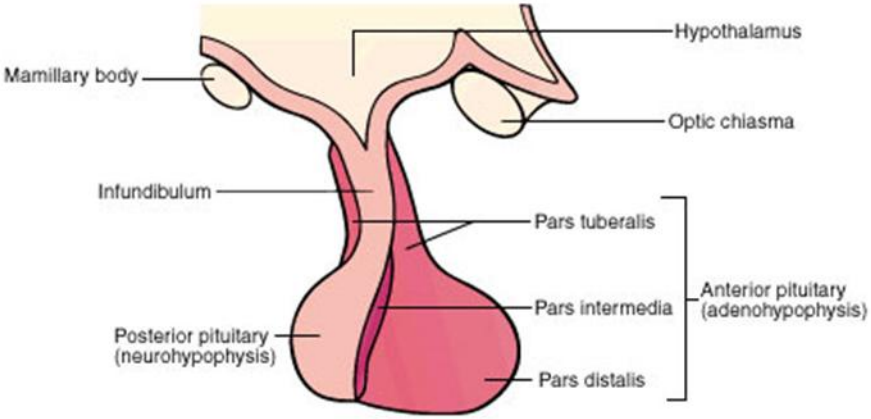

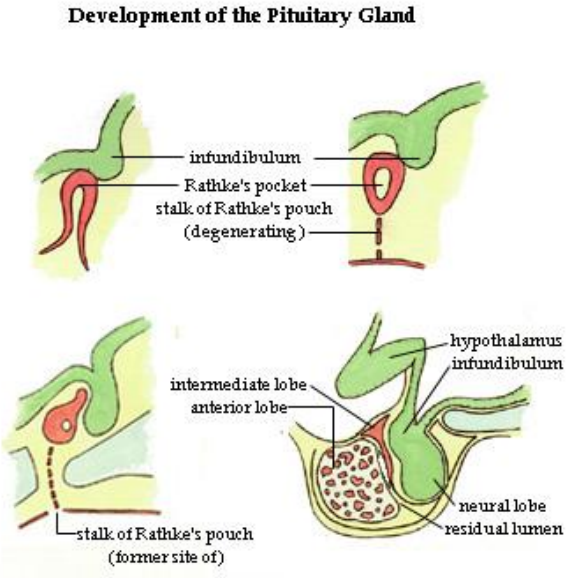

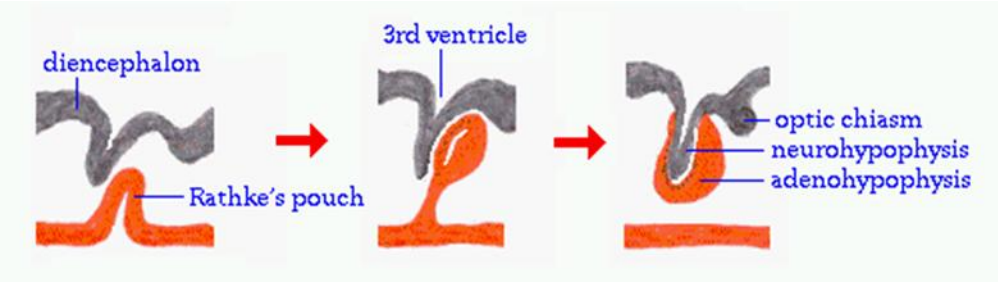

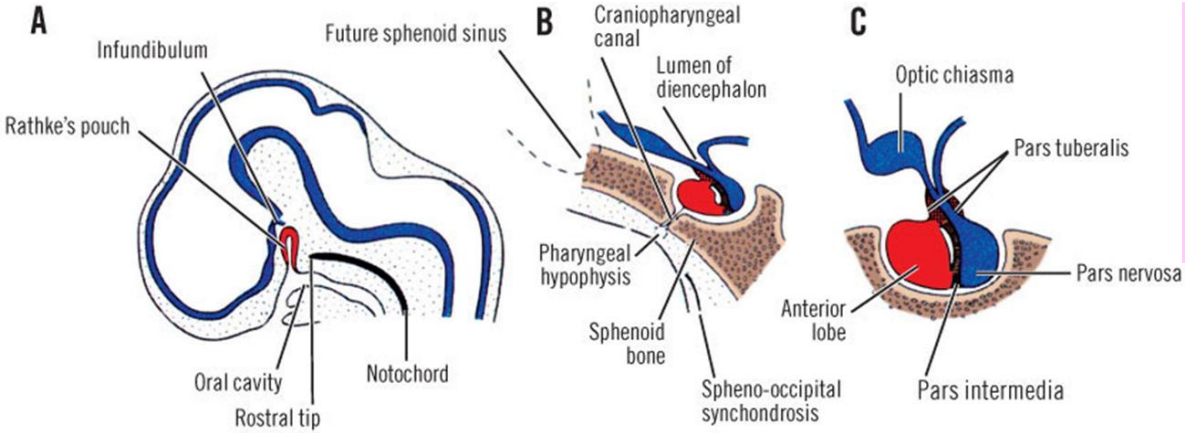

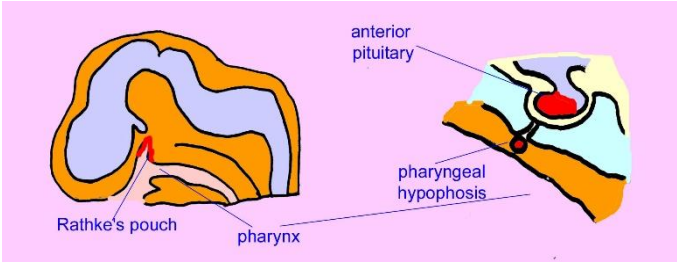

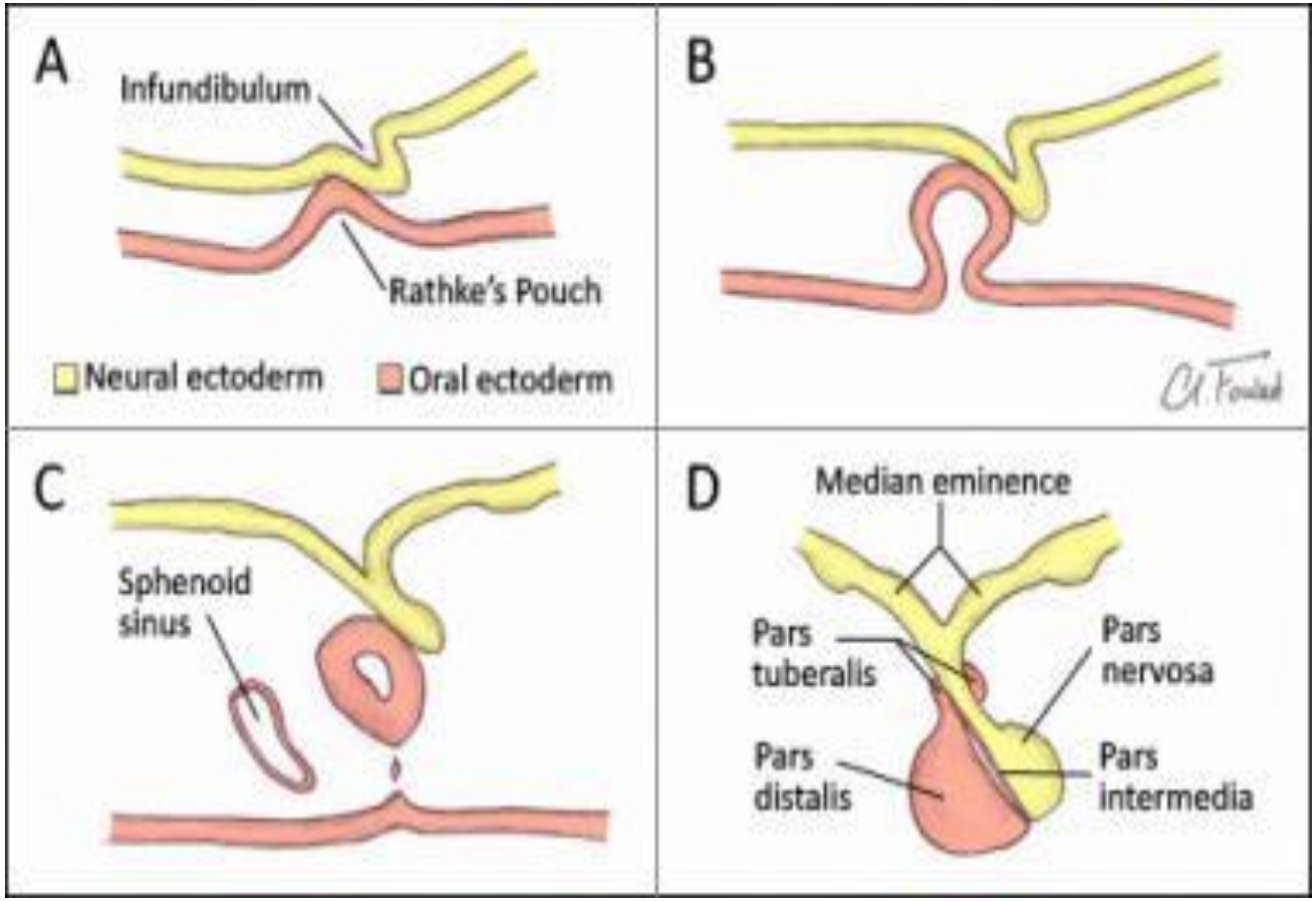
A
Infundibulum
Rathke's Pouch
Neural ectoderm
Oral ectoderm
B
C
Sphenoid sinus
D
Median eminence
Pars tuberalis
Pars nervosa
Pars distalis
Pars intermedia

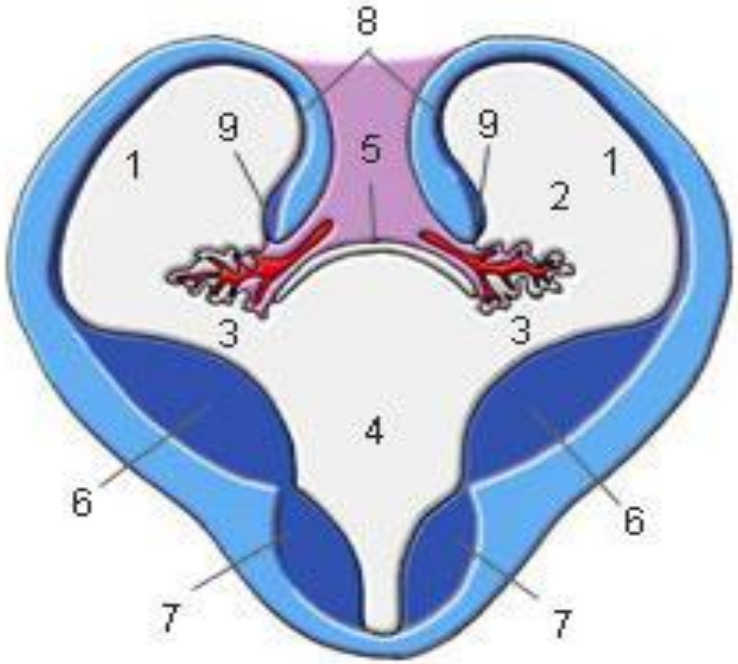

1. Lateral ventricle
2. Choroid plexus
3. Foramen of Monro
4. 3rd ventricle
5. Ependymal roof of the 3rd ventricle
6. Corpus striatum
7. Hypothalamus
8. Neopallium
9. Hippocampus

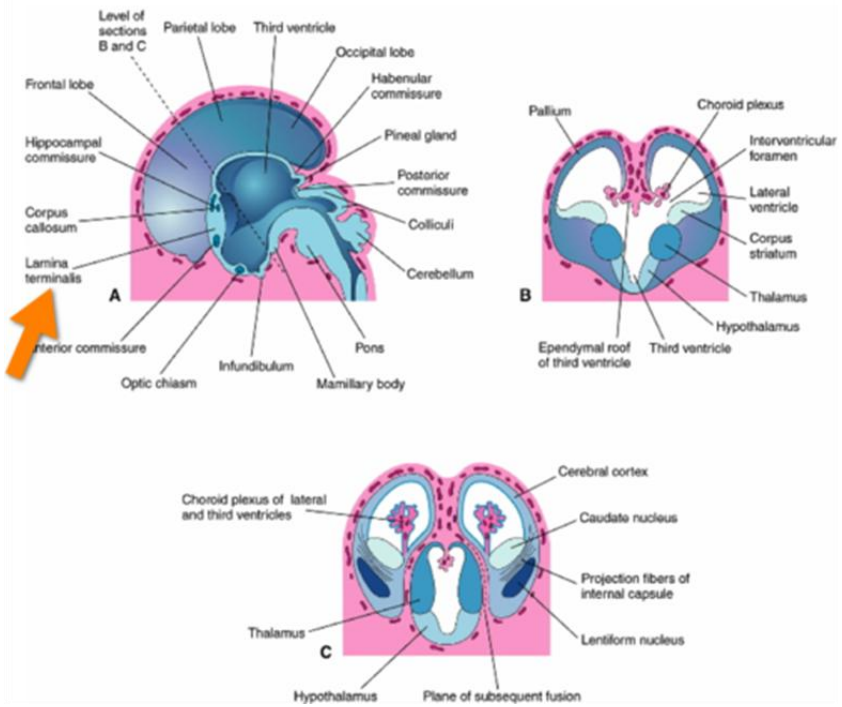
Level of sections B and C
Parietal lobe
Third ventricle
Occipital lobe
Frontal lobe
Habenular commissure
Hippocampal commissure
Pineal gland
Posterior commissure
Corpus callosum
Colliculi
Lamina terminalis
Cerebellum
A
Pons
Infundibulum
Optic chiasm
Mamillary body
Pallium
Choroid plexus
Interventricular foramen
Lateral ventricle
Corpus striatum
Thalamus
B
Hypothalamus
Ependymal roof of third ventricle
Third ventricle
Cerebral cortex
Choroid plexus of lateral and third ventricles
Caudate nucleus
Projection fibers of internal capsule
Thalamus
Lentiform nucleus
C
Hypothalamus
Plane of subsequent fusion

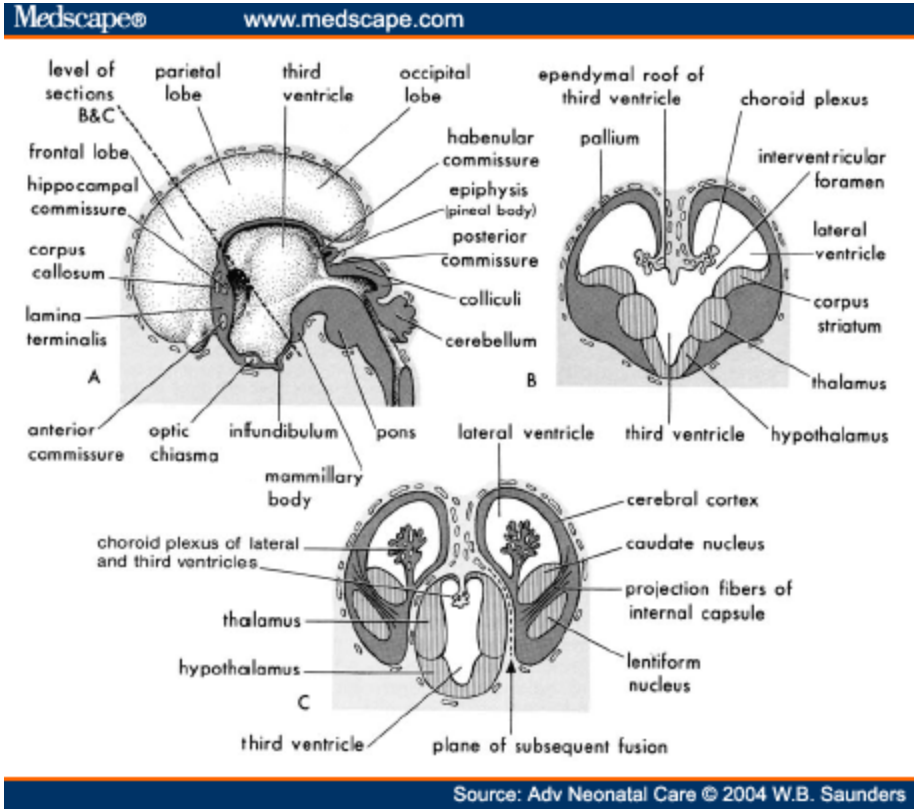
Medscape®
www.medscape.com
level of sections B&C
parietal lobe
third ventricle
occipital lobe
ependymal roof of third ventricle
choroid plexus
frontal lobe
habenular commissure
pallium
interventricular foramen
hippocampal commissure
epiphysis (pineal body)
lateral ventricle
corpus callosum
posterior commissure
corpus striatum
lamina terminalis
colliculi
cerebellum
A
B
thalamus
anterior commissure
optic chiasma
infundibulum
pons
lateral ventricle
third ventricle
hypothalamus
mammillary body
cerebral cortex
choroid plexus of lateral and third ventricles
caudate nucleus
projection fibers of internal capsule
thalamus
hypothalamus
lentiform nucleus
C
third ventricle
plane of subsequent fusion
Source: Adv Neonatal Care © 2004 W.B. Saunders

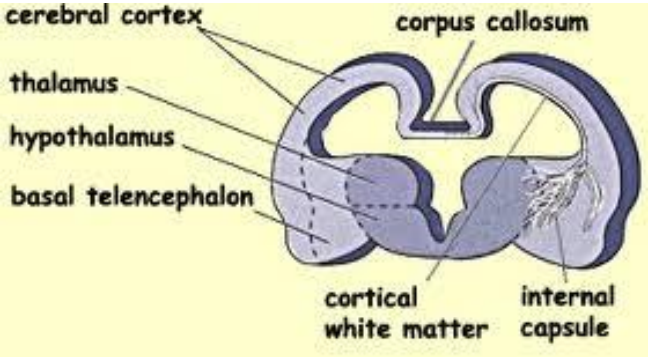
cerebral cortex
corpus callosum
thalamus
hypothalamus
basal telencephalon
cortical white matter
internal capsule

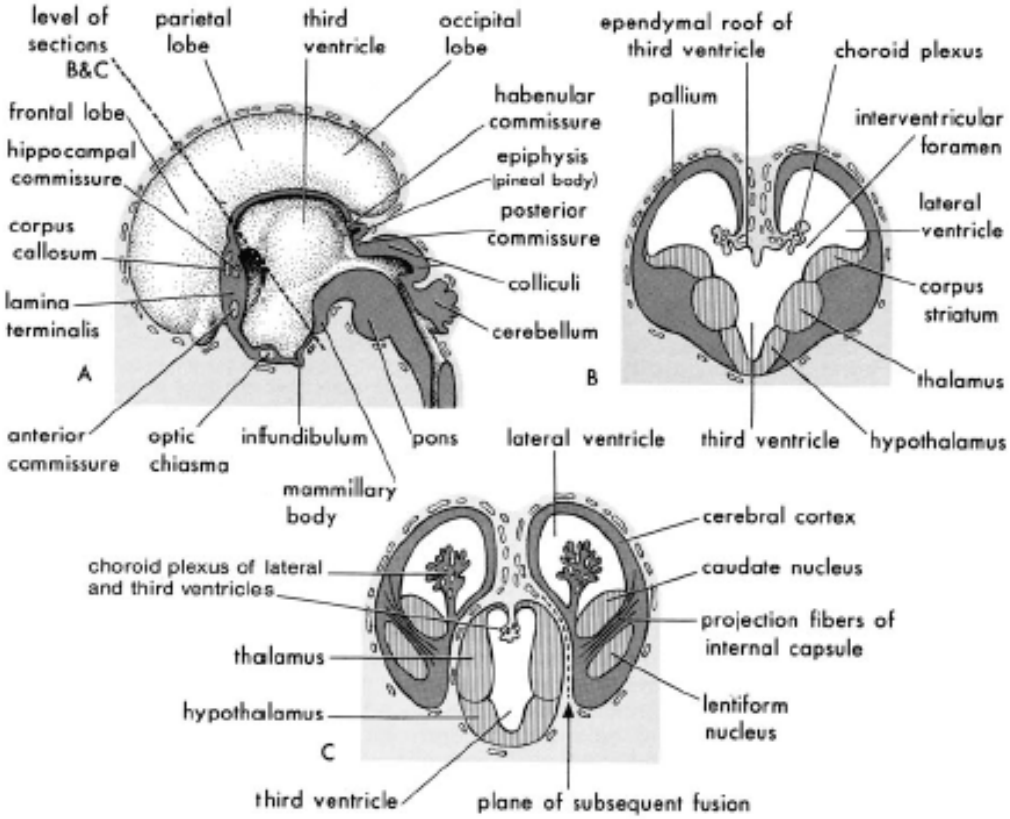

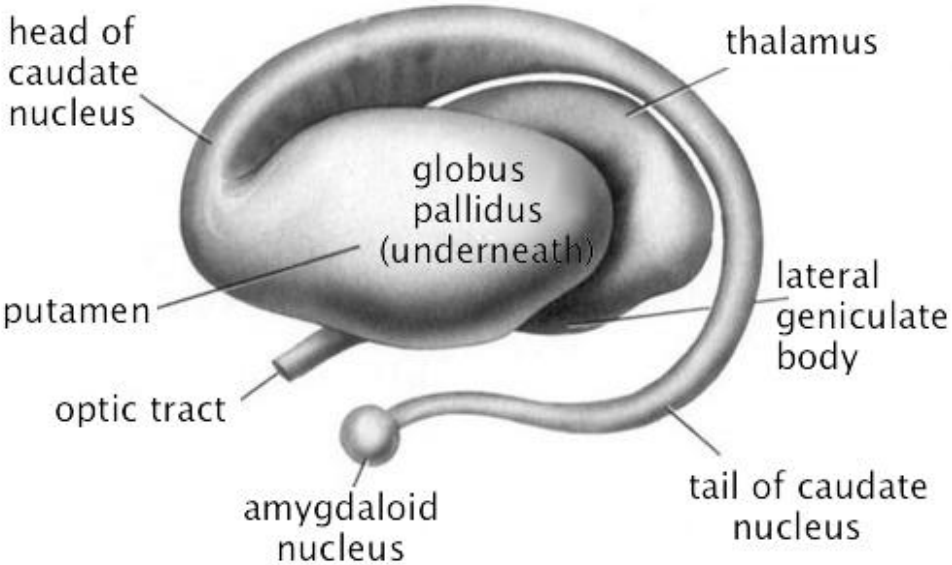
head of
caudate
nucleus
thalamus
globus
pallidus
(underneath)
putamen
lateral
geniculate
body
optic tract
amygdaloid
nucleus
tail of caudate
nucleus


cm
1
2
3

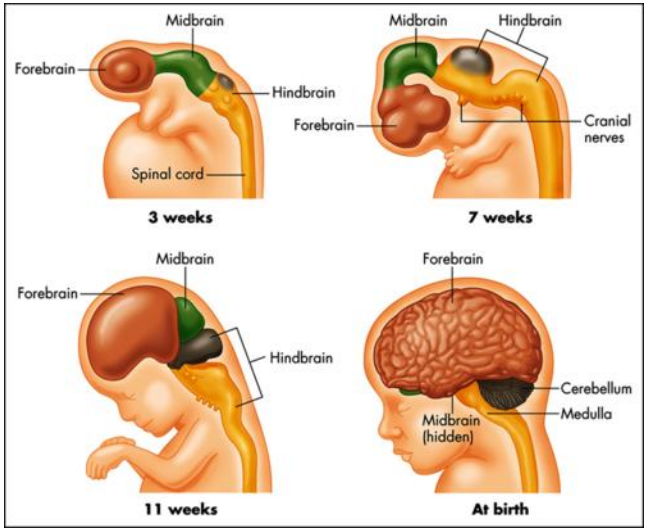
Midbrain
Forebrain
Hindbrain
Spinal cord
3 weeks
Midbrain
Hindbrain
Forebrain
Cranial nerves
7 weeks
Midbrain
Forebrain
Hindbrain
11 weeks
Forebrain
Cerebellum
Medulla
Midbrain (hidden)
At birth

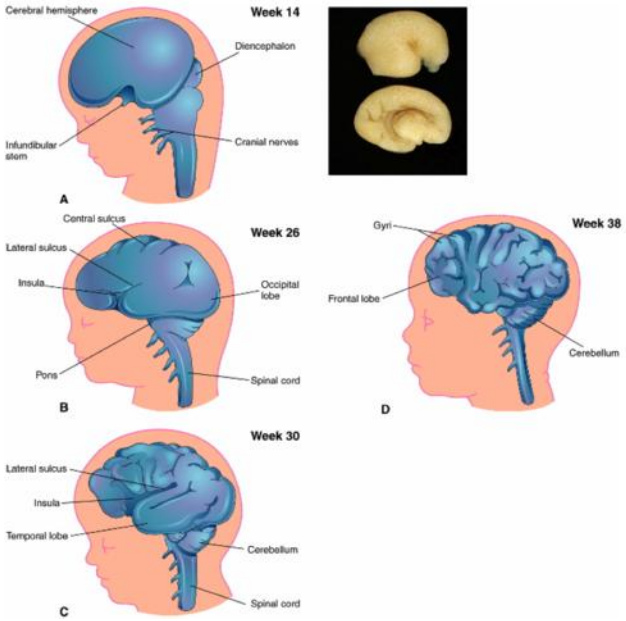
Cerebral hemisphere
Week 14
Diencephalon
Infundibular stem
Cranial nerves
A
Central sulcus
Week 26
Lateral sulcus
Insula
Occipital lobe
Pons
Spinal cord
B
Week 38
Gyri
Frontal lobe
Cerebellum
D
Week 30
Lateral sulcus
Insula
Temporal lobe
Cerebellum
Spinal cord
C

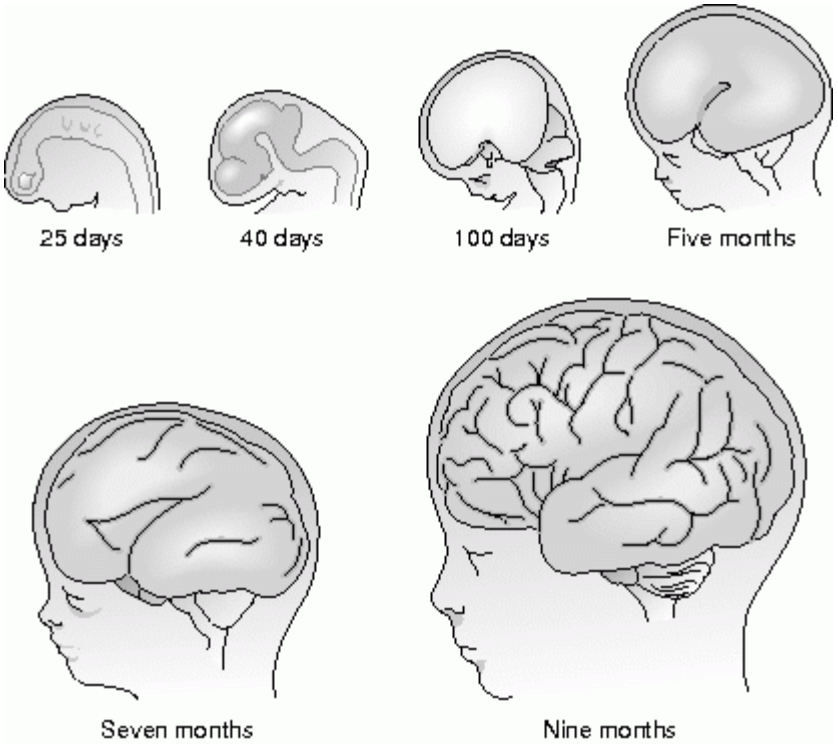
25 days
40 days
100 days
Five months
Seven months
Nine months

FORMATION OF CHOROID FISSURE

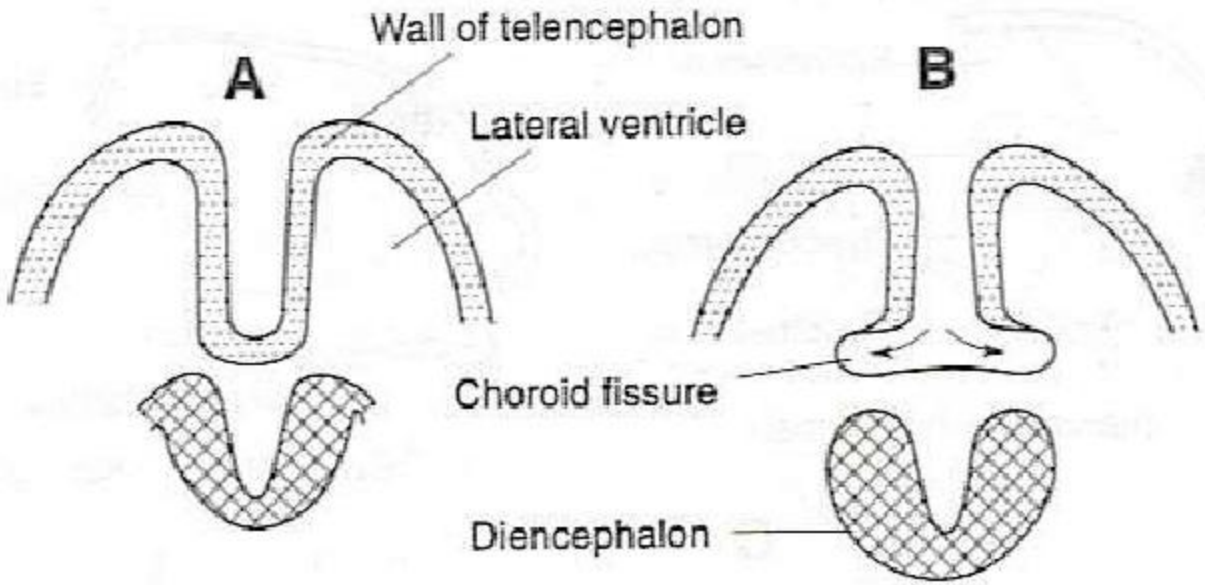

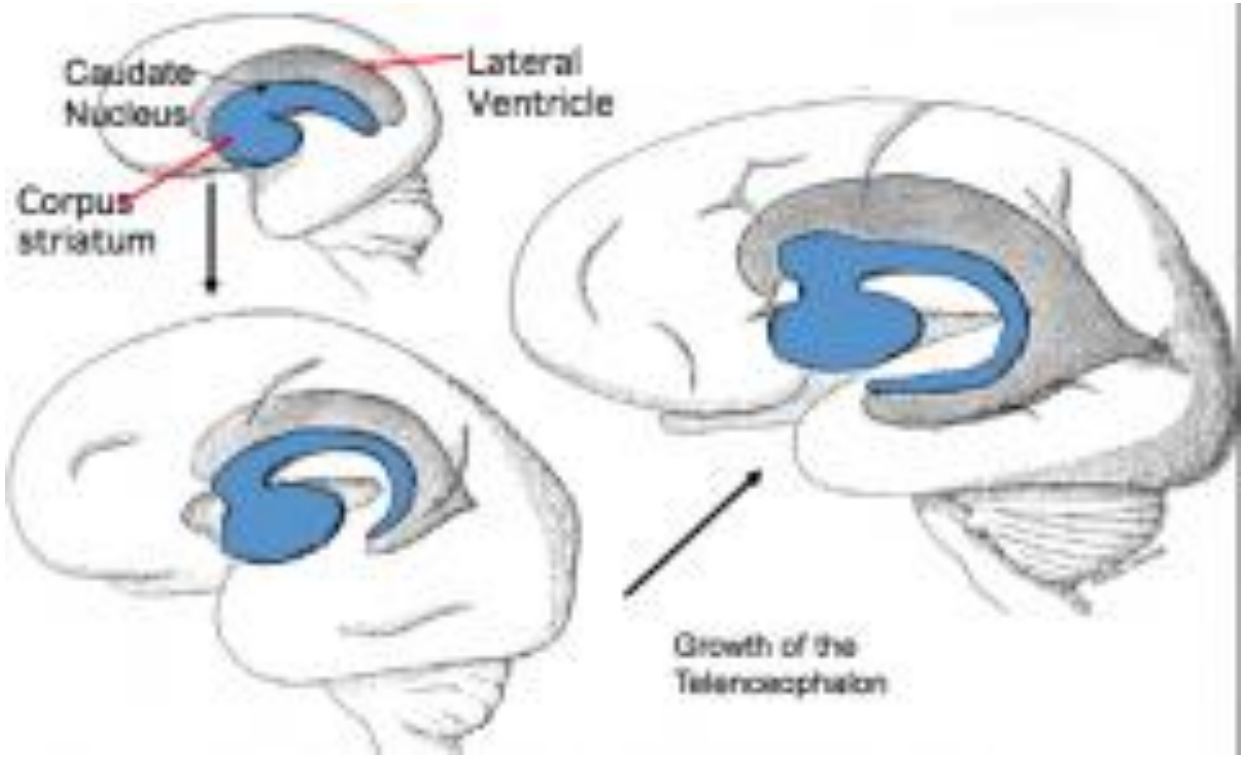
Caudate
Nucleus
Lateral
Ventricle
Corpus
striatum
Growth of the
Telencephalon

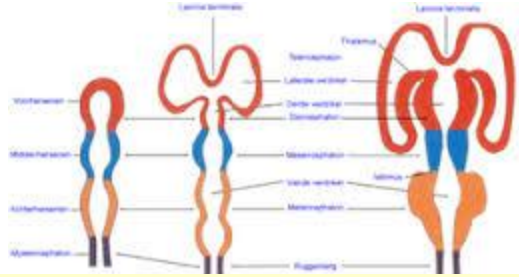

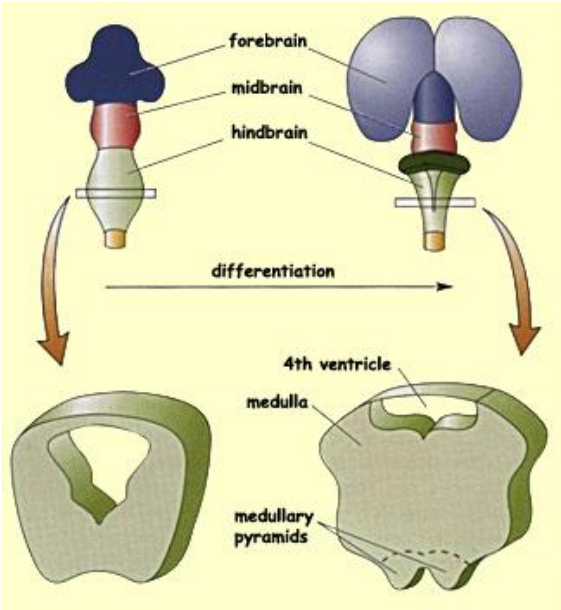
forebrain
midbrain
hindbrain
differentiation
4th ventricle
medulla
medullary pyramids

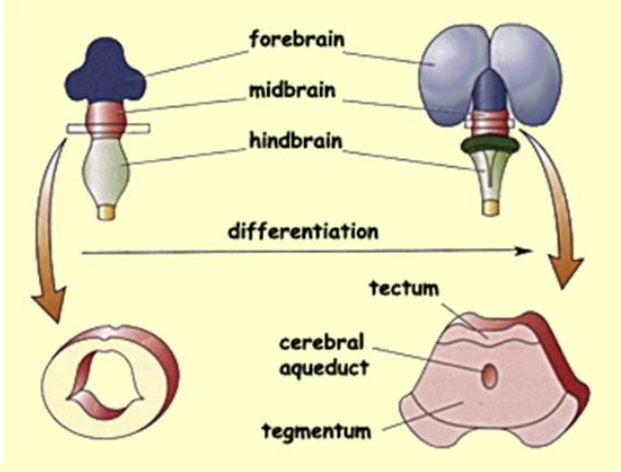
forebrain
midbrain
hindbrain
differentiation
tectum
cerebral aqueduct
tegmentum

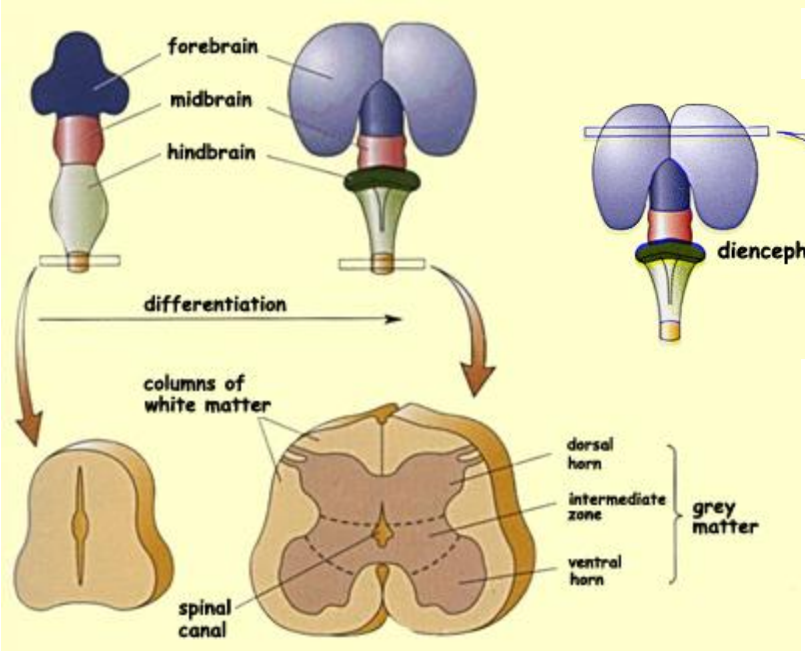
forebrain
midbrain
hindbrain
differentiation
columns of white matter
dorsal horn
intermediate zone
ventral horn
grey matter
spinal canal

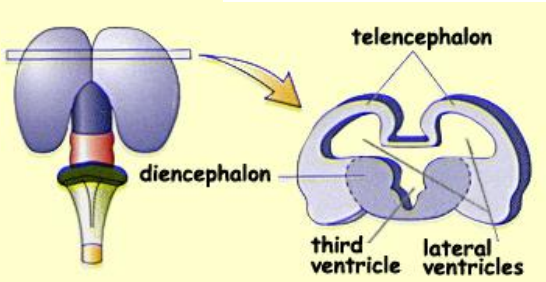
telencephalon
diencephalon
third ventricle
lateral ventricles

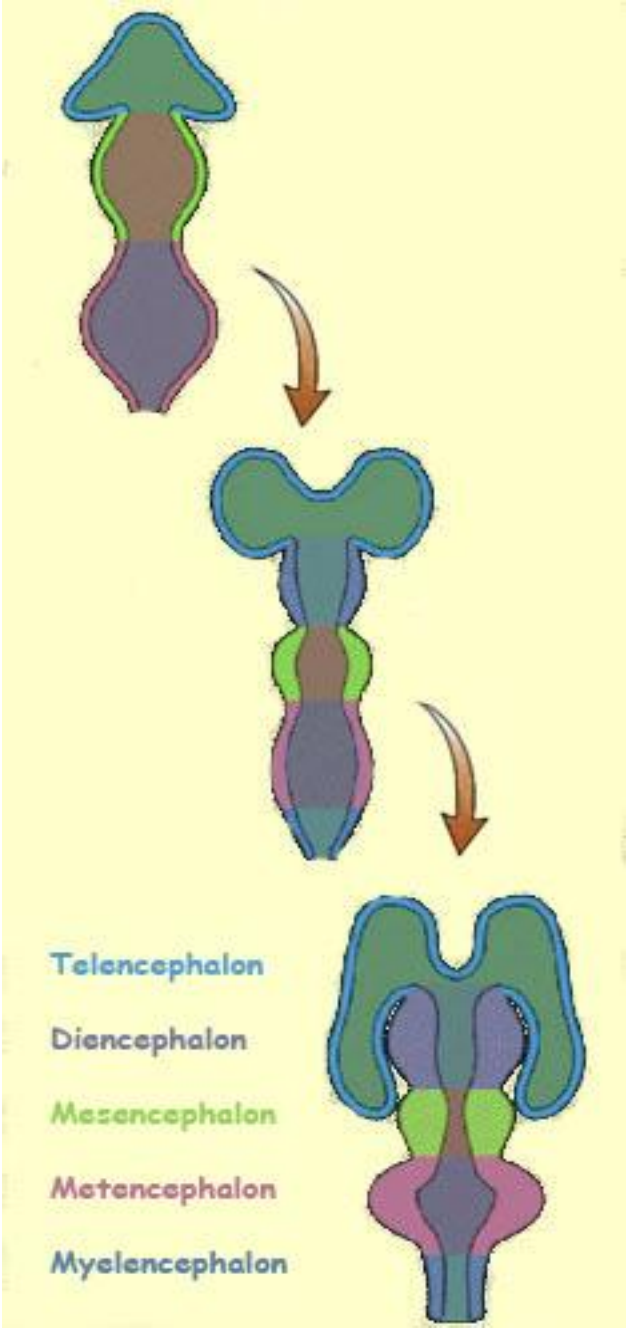
Telencephalon
Diencephalon
Mesencephalon
Metencephalon
Myelencephalon

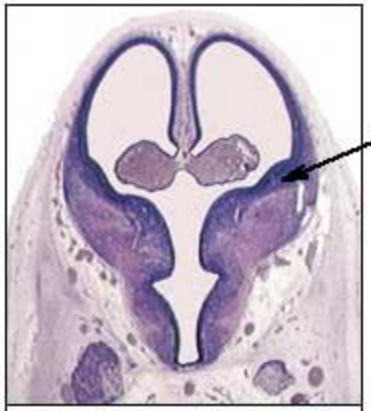

21mm, 8 wks (at IV Formamen)

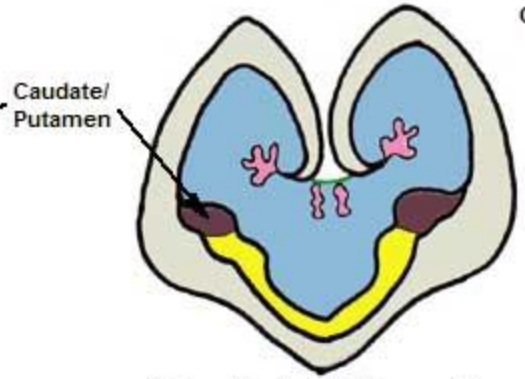

53mm, 10 wks (at IV Formamen)

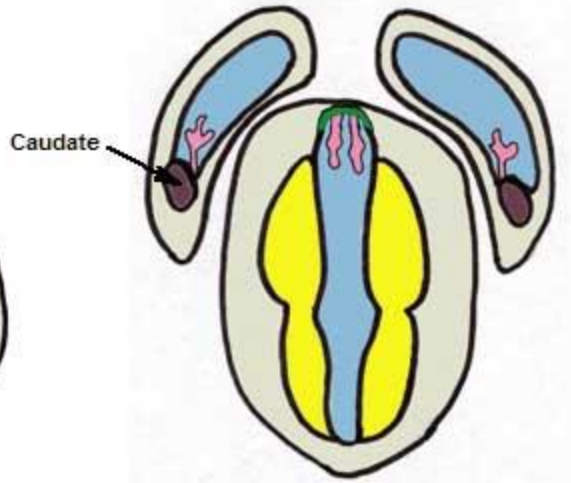

Early - Before secondary fusion of telen. & dien.
(Caudal to IV Formamen)

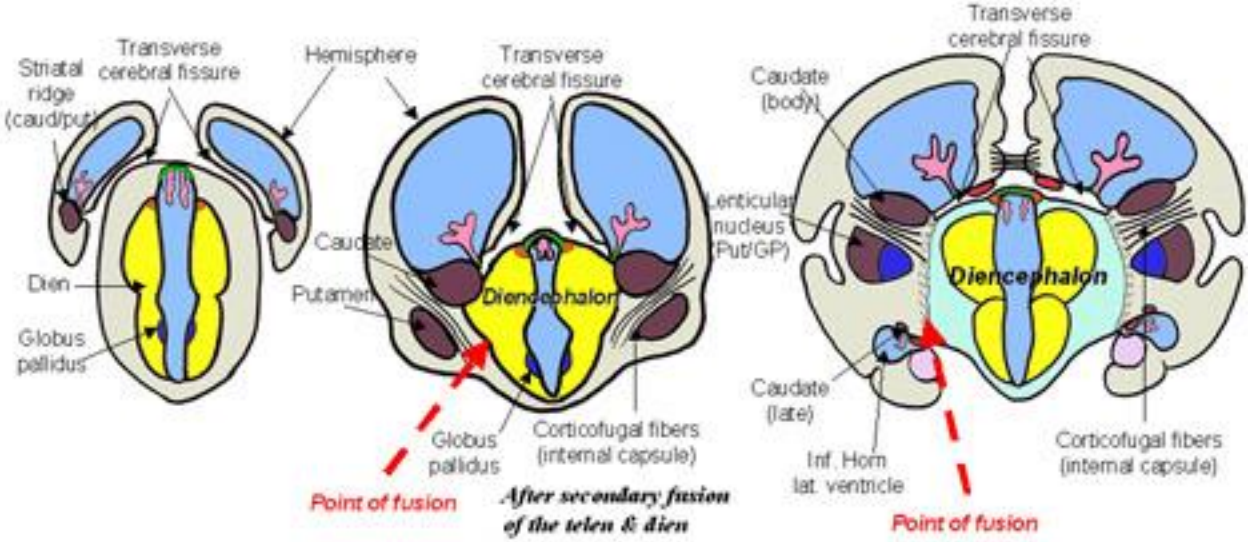

Semicircular ducts

Choroid plexus

Alar plate

Sulcus limitans

Basal plate

Ampullae

Cochlea

Skin

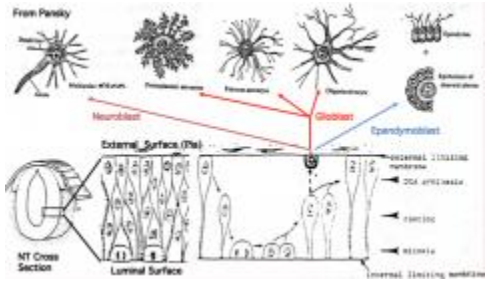

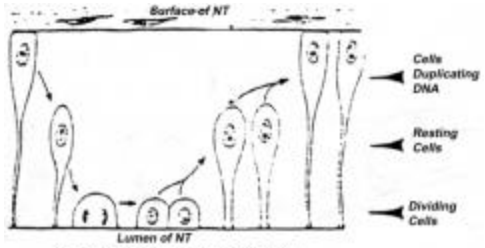

Cell Division Cycle of the Neuroepithelium